

## Sneaky Pancreatic Head Mass

Shetty Prathvi, Tauro Leo F, Jayaram Jnaneshwari

Received: 27 Sept 2011 / Accepted: 24 Nov 2011  
© OMSB, 2012

**A** 60 yrs old male presented to the Father Muller Medical College and Hospital, India, with dyspeptic symptoms. On physical examination, epigastric tenderness was present and ultrasound revealed an ill defined inhomogeneous hyper echoic lesion in the head of pancreas. Hemogram, serum amylase, serum lipase and liver function tests were all normal. Contrast-enhanced CT showed a homogeneous focal mass measuring about 5 × 6 cm in the pancreatic head, (Figs. 1a and b). The mass was isodense with fat tissue, with interlobular septa, and without central or peripheral contrast. Upper GI endoscopy revealed mild antral gastritis. The patient improved with antacids.

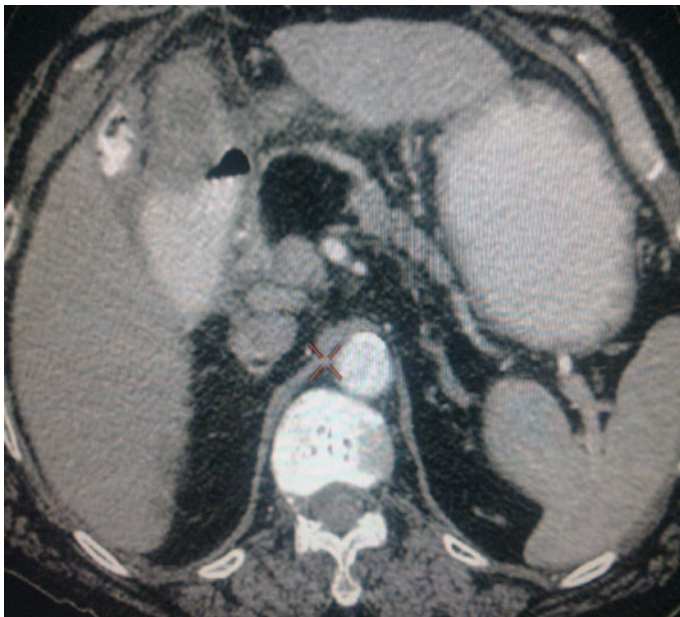


Figure 1a: Contrast-enhance Computer Tomography.

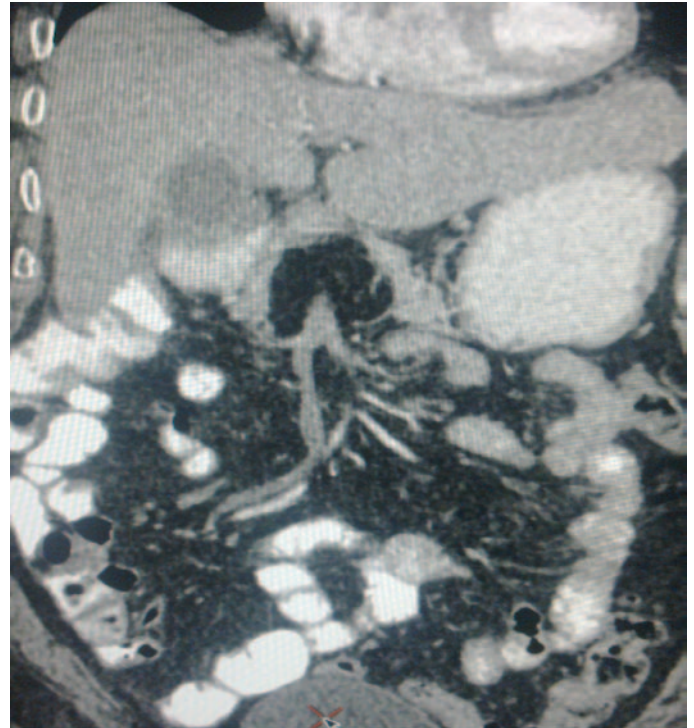


Figure 1b: Contrast-enhance CT Computer Tomography.

### Question

1. What is the diagnosis and management?

Answer on page 71

Shetty Prathvi ✉, Tauro Leo F, Jayaram Jnaneshwari  
Department of Surgery Father Muller Medical Collage and Hospital. Kankanady  
Mangalore 575002 Karnataka, India.  
E-mail: prathviz@gmail.com

## Answer

Lipoma of the pancreas

## Discussion

Typical CT findings are hypodensity (from -30 to -120 HU) and homogeneity, with no significant contrast enhancement and without infiltration of peri-pancreatic fat. Lipomas appear as hyperechoic on ultrasound with posterior acoustic attenuation, with some instances of hypoechogenicity. MRI is extremely helpful in detecting the presence or absence of macroscopic fat. On T1-weighted images, mature adipose tissue demonstrates high signal intensity and signal drop on fat suppressed sequence; while a T2-weighted image shows variable signal intensity with no enhancement on contrast images.<sup>1,2</sup>

Pancreatic lipoma is a rare condition usually found incidentally. They are mostly asymptomatic and appear as a well circumscribed, encapsulated homogenous adipose mass within the pancreatic parenchyma. Imaging features of pancreatic lipoma are diagnostic and do not need histopathological evidence.<sup>3</sup> In some instances, EUS-FNA is required to differentiate between the benign lipoma and neoplastic lesions, especially lipomatous malignancies.<sup>4</sup>

There are not many differential diagnosis for pancreatic lipoma on CT scan; few include focal fatty infiltration of the pancreas, teratoma (mature dermoid cyst), and liposarcoma. Histopathological evidence is only needed if there is rapid progress in size to rule out liposarcoma.<sup>5</sup> Surgical intervention is done if there are signs of ductal or vessel obstruction and hemorrhage.

The condition may be treated with a Whipple procedure, distal pancreatectomy, or by enucleation if the tumors are amenable; if not, palliative by-pass surgery is performed.<sup>6,7</sup>

## Acknowledgements

The authors reported no conflict of interest and no funding was received for this work.

## References

1. Karaosmanoglu, Devrim MD, Karcaaltincaba, Musturay MD, Akata, Deniz MD, et al. Pancreatic lipoma computed tomography diagnosis of 17 patients and follow-up. *Pancreas*. 2008 May; 36:434-6.
2. Katz DS, Nardi PM, Hines J, Barckhausen R, Math KR, Fruauff AA, et al. Lipomas of the pancreas. *AJR Am J Roentgenol* 1998 Jun;170(6):1485-1487.
3. Temizoz O, Gencellac H, Unlu E, Kantarci F, Umit H, Demir MK. Incidental pancreatic lipomas: computed tomography imaging findings with emphasis on diagnostic challenges. *Can Assoc Radiol J* 2010 Jun;61(3):156-161.
4. Suzuki R, Irisawa A, Hikichi T, Shibukawa G, Takagi T, Wakatsuki T, et al. Pancreatic lipoma diagnosed using EUS-FNA. A case report. *JOP* 2009;10(2):200-203.
5. Raut CP, Fernandez-del Castillo C. Giant lipoma of the pancreas: case report and review of lipomatous lesions of the pancreas. *Pancreas* 2003 Jan;26(1):97-99.
6. Zhan HX, Zhang TP, Liu BN, Liao Q, Zhao YP. A systematic review of pancreatic lipoma: how come there are so few cases? *Pancreas* 2010 Mar;39(2):257-260.
7. Salman Monte Z, Ruiz-Cabello Jiménez M. P. Pardo Moreno and P. Montoro Martínez. Lipoma of the pancreas: diagnosis and management of these rare tumors. *Rev Esp Enferm Dig* 2006 Nov;98:11.