

Use of Infrared Thermography for Assessing Tissue Viability in Extensive Digital Necrosis by Raynaud's Phenomenon

Mario Aurelio Martínez-Jiménez*, Natalia Sánchez-Olivo, Patricia Aurea Cervantes-Báez, Eleazar Samuel Kolosovas-Machuca and Carlos Abud-Mendoza

Autonomous University of San Luis Potosi: Universidad Autonoma de San Luis Potosi

Received: 10 July 2025

Accepted: 5 November 2025

*Corresponding author: mario.jimenez@uaslp.mx

DOI 10.5001/omj.2029.21

Abstract

Raynaud's syndrome is a vasomotor disorder characterized by episodes of vasoconstriction in response to cold or emotional stress, mainly affecting the extremities. It can lead to complications and cause severe digital necrosis. Infrared thermography is a tool that evaluate skin perfusion and the detection of vascular alterations characteristic of this syndrome, facilitating both diagnosis and the monitoring of the patient's progress. We present a 44-year-old man, who attended a rheumatology consultation with bilateral digital necrosis. The necrosis became self-limiting, and infrared thermography was performed, revealing the boundaries of hypoperfusion in the affected fingers, which were partially surgically removed.

Keywords: Raynaud's syndrome, digital necrosis, dermatomyositis, infrared thermography, Raynaud's phenomenon.

Introduction

Raynaud's syndrome is a vasomotor disorder characterized by episodes of vasoconstriction in response to cold or emotional stress, mainly affecting the extremities.¹ This syndrome is classified into two types: primary, which occurs in isolation without an underlying disease, and secondary, which is associated with other pathologies, particularly autoimmune diseases. In the context of autoimmune diseases, such as dermatomyositis, Raynaud's phenomenon can become complicated and lead to severe digital necrosis, significantly worsening the clinical condition. Clinically, it presents with color changes in the fingers and symptoms such as tingling and pain. It can be asymmetrical and often affects only one finger.²⁻⁴

Infrared thermography is a valuable diagnostic tool that allows the assessment of skin perfusion and the detection of vascular alterations characteristic of this syndrome, facilitating both diagnosis and monitoring of the patient's progress.⁵⁻¹² Additionally, psychological and somatic consequences of digital amputations highlight the importance of using precise diagnostic methods, including thermography, to guide therapeutic strategies.¹³

Case Report

A 44-year-old professional pianist presented to the rheumatology clinic with bilateral digital necrosis. The initial symptoms had begun five months earlier and were associated with the recent onset of dermatomyositis. The patient was followed for two years, demonstrating good perfusion of the amputation line of the 18 fingers that had undergone partial amputation (Figure 1). The necrosis became self-limiting, and infrared thermography revealed areas of hypoperfusion in the affected fingers, which were subsequently surgically removed. Figure 2)

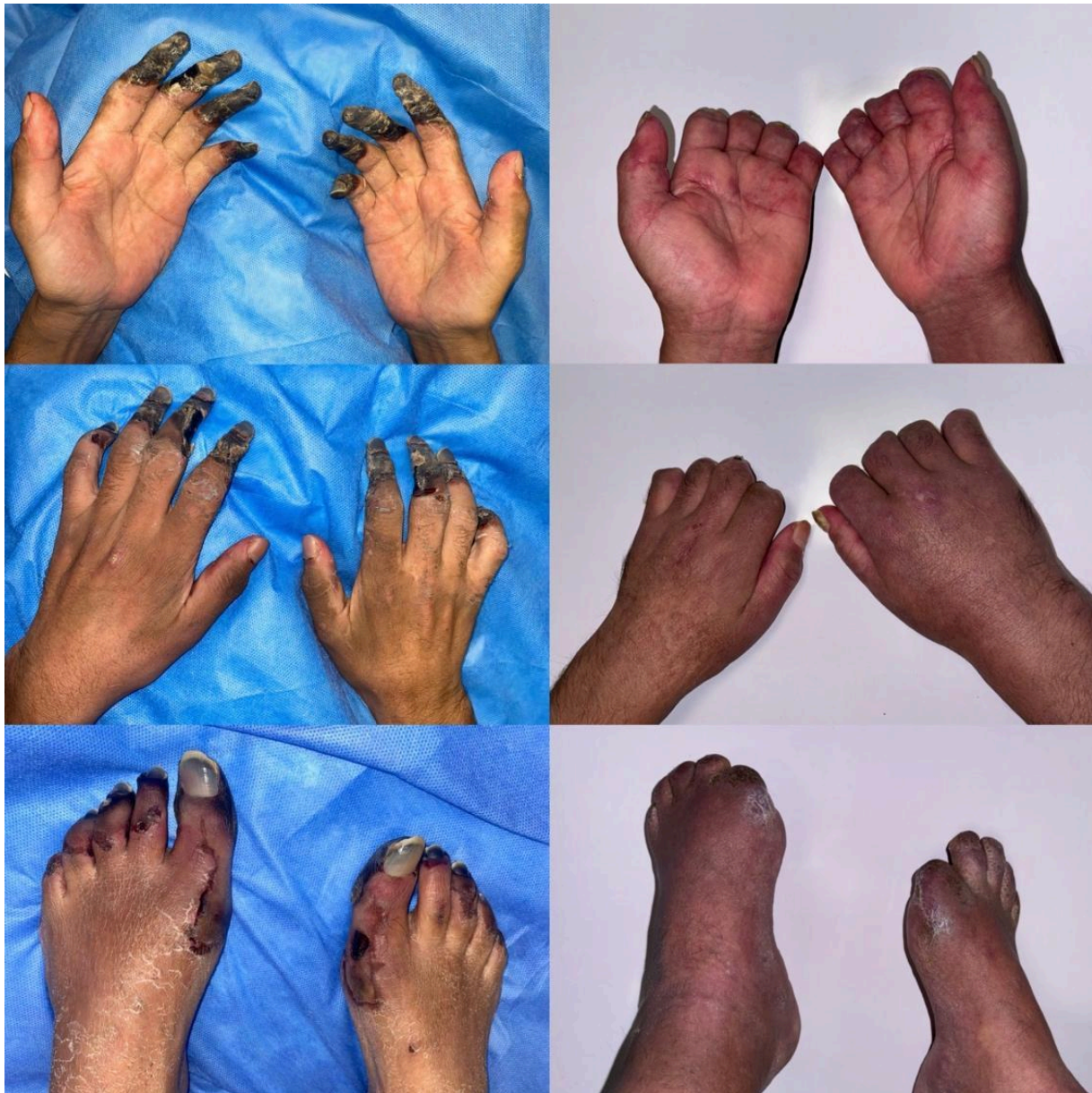

Figure 1: Necrosis of the tips of 18 fingers after not continuing rheumatology treatment for 5 months, months of follow-up after partial amputations of the 18 fingers, demonstrating good quality of distal tissue.

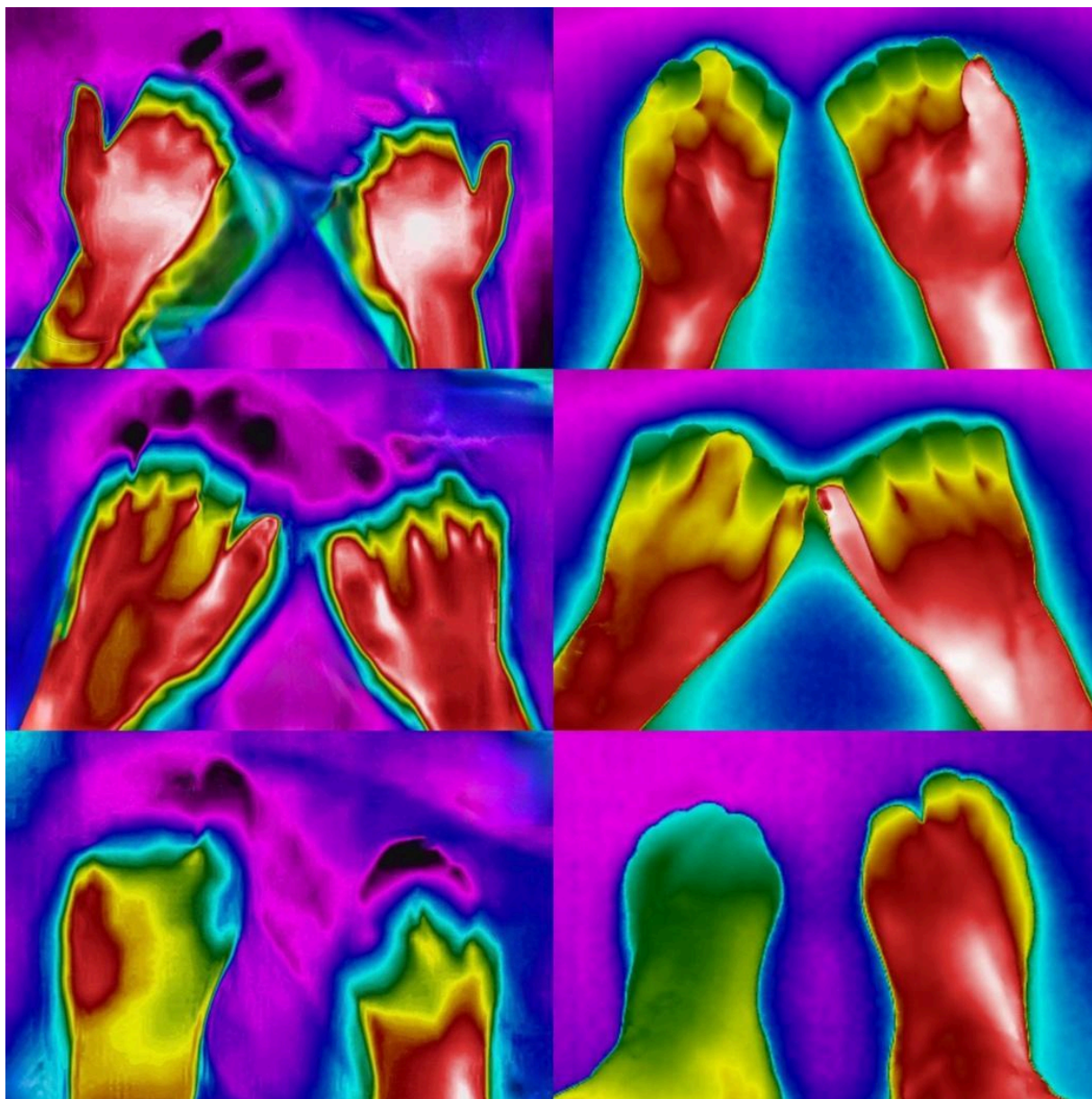


Figure 2: Infrared thermography recording, showing a decrease in perfusion at the distal joint of the phalanges on the color map, corresponding to a difference of more than 5 degrees compared to healthy tissue. Color map of the thermography without the presence of necrosis and with a more homogeneous record of the distal temperature.

On physical examination, both upper limbs were free of edema and the ulnar and radial pulses were palpable. Laboratory studies were positive for antinuclear antibodies (ANA) at 1:640 and melanoma differentiation-associated protein 5 (anti-MDA5). Creatine kinase levels were 205 units per liter (reference value, <170). The patient was treated with mycophenolic acid, verapamil, sildenafil, and prednisone; however, he reported voluntarily discontinuing treatment two weeks after initiating it. It is worth noting that during his most recent hospitalization, an invasive sympathectomy procedure was proposed. The patient declined the procedure and requested voluntary discharge.

Discussion

Secondary Raynaud's syndrome can lead to serious complications such as digital necrosis, which requires a multidisciplinary therapeutic approach. Infrared thermography is a valuable tool in the diagnosis and management of this phenomenon, as it provides accurate information on skin perfusion, helping to assess the severity of vascular damage. Patient education and prevention of triggering factors are essential for symptom control, complemented by pharmacological and immunomodulatory therapeutic options to optimize clinical management ^{1, 5, 6}.

Secondary Raynaud's phenomenon may be associated with autoimmune diseases, where endothelial dysfunction and the presence of autoantibodies, such as anti-MDA5, contribute to an exaggerated vasomotor response. The complication of digital necrosis is rare but serious, associated with increased morbidity and, in advanced cases, may lead to amputations.^{3,4} Management of Raynaud's phenomenon ranges from preventive measures, such as avoiding cold exposure and reducing stress, to the use of calcium channel blockers such as verapamil. In severe cases, vasodilators and immunosuppressive agents, such as mycophenolate acid, are employed ^{2, 4}. The pathophysiology of Raynaud's phenomenon includes a vasoconstrictor response mediated by sympathetic hyperactivity. In the secondary setting, endothelial inflammation and specific autoantibodies, such as anti-MDA5, play a crucial role in exacerbating vascular episodes, contributing to the development of ischemia and necrosis ^{3, 5}.

Thermography can guide the efficacy of treatment by monitoring changes in digital perfusion. Infrared thermography is a noninvasive technique that measures skin surface temperature, reflecting underlying blood perfusion. In Raynaud's phenomenon, thermography allows visualization of low temperature areas on the fingers during vasospasm episodes, facilitating diagnosis and assessment of severity ^{5 – 12}. Moreover, recent studies support personalized treatment approaches for cases involving digital amputations, emphasizing the importance of thermographic monitoring to guide clinical decisions and improve outcomes ¹⁴.

Conclusion

In Raynaud's phenomenon occurs low temperature areas on the fingers during vasospasm episodes. In this case, thermography is a complement to the clinical assessment in a patient with extensive necrosis of several fingers, facilitating diagnosis and assessment of severity, trying to provide objectivity to the level of amputation and to be as conservative as possible, it is also a practical and reliable tool for long-term follow-up.

Disclosure

The authors declare that they have no conflict of interest. The authors have obtained informed consent from the patients or subjects referred to in the article. This document is in the possession of the corresponding author.

References

1. Wigley FM. Clinical practice. Raynaud's Phenomenon. *N Engl J Med*. 2002; 26;347(13):1001- 1008.
2. Charbit L, Busztein AC, Mohamed S, Kaminsky P, Lerondeau B, Barbaud A, et al. Extensive digital necrosis during dermatomyositis associated with MDA-5 antibodies. *Ann Dermatol Venereol* 2016;143(8-9):537-542.
3. Yoshida A, Gono T, Okazaki Y, Shirai Y, Takeno M, Kuwana M. Severe digital ischemia as an unrecognized manifestation in patients with antisynthetase autoantibodies: Case series and systemic literature review. *J Scleroderma Relat Disord* 2022;7(3):204-216.

4. Ahijón-Lana M, Baragaño-Ordoñez E, Veiga-Cabello R, de la Cruz-Tapidor C, Carreira PE. Treatment of Raynaud phenomenon and ischemic ulcers associated to systemic sclerosis with hyperbaric oxygen. *Reumatol Clin (Engl Ed)* 2022;18(4):246-248.
5. Linberg L, Kristensen B, Eldrup E, Thomsen JF, Jensen LT. Infrared thermography as a method of verification in Reynaud's Phenomenon. *Diagnostics (Basel)* 2021;11(6):981.
6. Chaparro YC, González-Gómez A, Carvajal-Flechas F, Rojas C, Darío-Mantilla R, Rojas-Villarraga A. Detection of vascular changes in Raynaud's phenomenon when capillaroscopy and thermography are used. Systemic literature review. *Rev Colomb Reumatol* 2023;30(2):137-149.
7. Lindberg L, Kristensen B, Thomsen JF, Eldrup E, Jensen LT. Characteristic features of infrared thermographic imaging in primary Reynaud's Phenomenon. *Diagnostics (Basel)* 2021;11(3):558.
8. Schnhfried O, Vacariu G, Lang T, Korpan M, Kiener HP, Fialka-Moser V. Thermographic parameters in the diagnosis of secondary Raynaud's phenomenon. *Arch Phys Med Rehabil* 2000;81(4):495-499.
9. Branco JH, Branco RL, Siqueira TC, de Souza LC, Dalago KM, Andrade A. Clinical applicability of infrared thermography in rheumatic diseases: A systemic review. *J Therm Biol* 2022;104:103172.
10. Cai W, Yang Q, Han D, Chen Z, Cheng Y. Application and prospects of infrared thermography in rheumatic diseases. *Beijing Da Xue Bao Yi Xue Ban.* 2024;56(6):1132-1136.
11. Carriere ME, de Haas LE, Pijpe A, Meij-de Vries A, Gardien KL, va Zuijlen PP, et al. Validity of thermography for measuring burn wound healing potential. *Wound Repair Regen* 2020;28(3):347-354.
12. Martínez-Jiménez MA, Ramírez-GarcíaLuna JL, Kolosovas-Machuca S, Drager J, González FJ. Development and validation o fan algorithm to predict the treatment modality of burn wounds using thermographic scans: prospective cohort study. *PLoS One* 2018;13(11):e0206477.
13. Skoff H, Skoff H. The psychological and somatic consequences of digital amputation. *Plast Reconstr Surg Glob Open* 2022;10(6):e4387.
14. Dastagir N, Obed D, Dastagir K, Vogt PM. Personalized treatment decisions for traumatic proximal finger amputations: a retrospective cohort study. *J Pers Med* 2023;13(2):215.