

# Hair Transplant Causing a Scalp Arteriovenous Fistulae: A Case Report

Maryam Al Issai<sup>1</sup>, Edwin Stephen<sup>2\*</sup>, Faisal Al Azri<sup>3</sup>, Alok Mittal<sup>3</sup>, Ibrahim Abdelhady<sup>2</sup>, Hanan Al Maawali<sup>4</sup> and Khalifa Al Wahaibi<sup>2</sup>

<sup>1</sup>General Foundation Program, Oman Medical Specialty Board, Muscat, Oman

<sup>2</sup>Vascular surgery unit, Sultan Qaboos University Hospital, Muscat, Oman

<sup>3</sup>Interventional radiology, Sultan Qaboos University Hospital, Muscat, Oman

<sup>4</sup>Clinical nurse specialist, Sultan Qaboos University Hospital, Muscat, Oman

Received: 28 December 2024

Accepted: 16 February 2025

\*Corresponding author: [edwinmay2013@gmail.com](mailto:edwinmay2013@gmail.com)

DOI 10.5001/omj.2028.15

## Abstract

An arteriovenous fistula [AVF] is an abnormal fistulous communication between branches of the arteries and draining veins anywhere in the body. Scalp arteriovenous fistulae following hair transplantation are considered extremely rare with few reported cases in literature. We share our experience with 2 cases. The first a 38-year-old gentleman, a 2-month history of a pulsatile right sided scalp swelling, dilated veins and a CT angiogram showing an iatrogenic AVF; treated successfully with embolization using glue and coils. The second patient a 36-year-old male, had a similar finding, however at the time of presentation the AVF was thrombosed. To the best of our knowledge these are the first reported cases from Oman.

**Keywords:** Iatrogenic, arteriovenous, AVF, hair, transplant, treatment, Oman, Middle East

## Case Reports

### Case one

A 38-year-old gentleman with no past medical history or comorbidities underwent hair transplant surgery in January 2023. He presented with a prominent pulsatile right sided subcutaneous scalp swelling 2 months following the procedure that was progressively increasing in size, over the temporal region. This was associated with hearing the pulsations suggestive of vascular tinnitus. He did not report a syncopal attack or neurological symptoms. Clinically he is a healthy young gentleman with no features of a connective tissue disorder. Local examination revealed a pulsatile swelling with dilated veins in the right temporo-parietal region [Figure1]. A CT angiography [CTA] revealed multiple dilated tortuous vessels seen in the affected region. There was no obvious fistulous communication with the right superficial temporal artery [STA]. Other findings included significant thickening of the soft tissue of the scalp more marked on the right side with multiple dilated vascular structures identified in the entire scalp more marked on the right side. Features were suggestive of an AVF [Figure2].

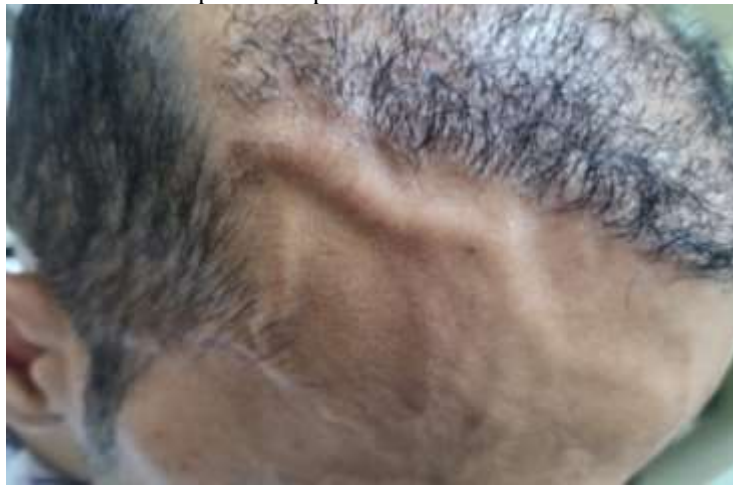The patient was informed about the findings and options of treatment, which included angioembolization or surgical excision. Our preference being the former. Associated risks/ complications including and not limited

to stroke, bleeding, infection at the access site, arterial dissection, thrombosis, post procedural pain and headache, recurrence & re-intervention were explained to the patient. He agreed for angioembolization.

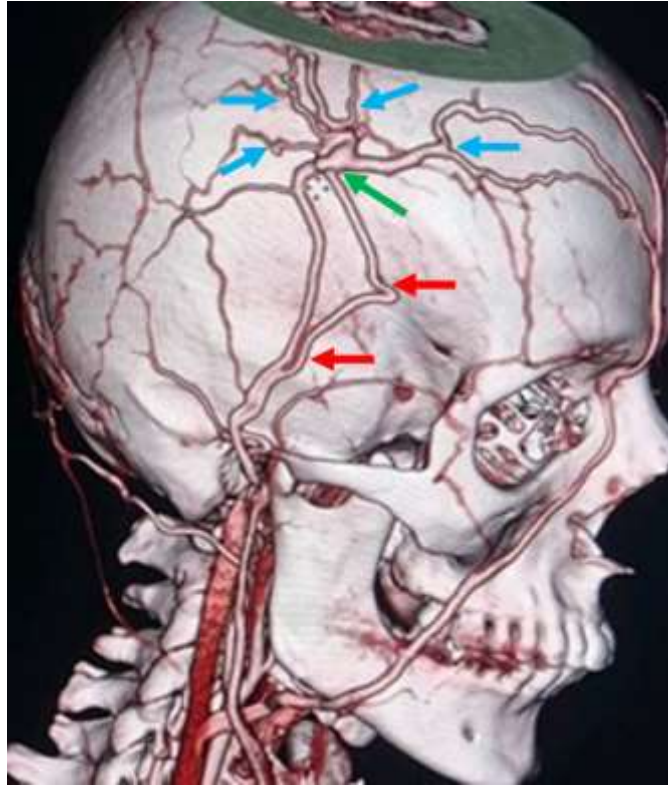
The procedure was carried out under local anesthesia [LA], through the right common femoral artery; selective angiogram of bilateral internal carotid and external carotid arteries were performed. Multiple arterial feeders and arteriovenous fistula were noted in scalp soft tissue from the right STA in the parieto-temporal region; the occipital region and the midline over the frontal region with a feeder from the left ophthalmic artery. Super-selective angioembolization of the right superficial temporal and occipital artery were performed using glue and coils] Figure3]. There were no immediate post-procedure complications. He was discharged home the following day on analgesia for a dull occipital headache that he had, with a good cosmetic result [Figure 4].

The AVF in the frontal region was not addressed as this was found only on imaging and had a feeder from the ophthalmic artery. A decision to clinically follow-up the patient was made and if the size grew, to inject glue percutaneously under ultrasound guidance.

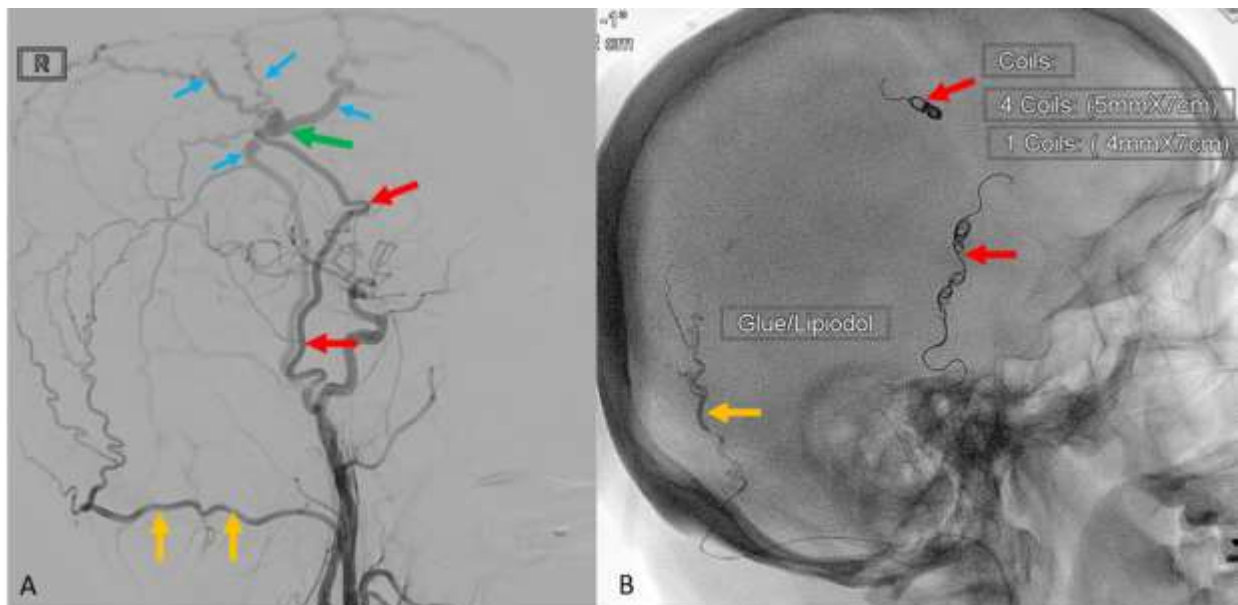
The patient at 8-week follow-up remains pleased with the outcome and headache has reduced significantly with no visible swelling in the frontal region. Patient followed up with a telephonic conversation and would come if he had any concerns to our out-patient department.



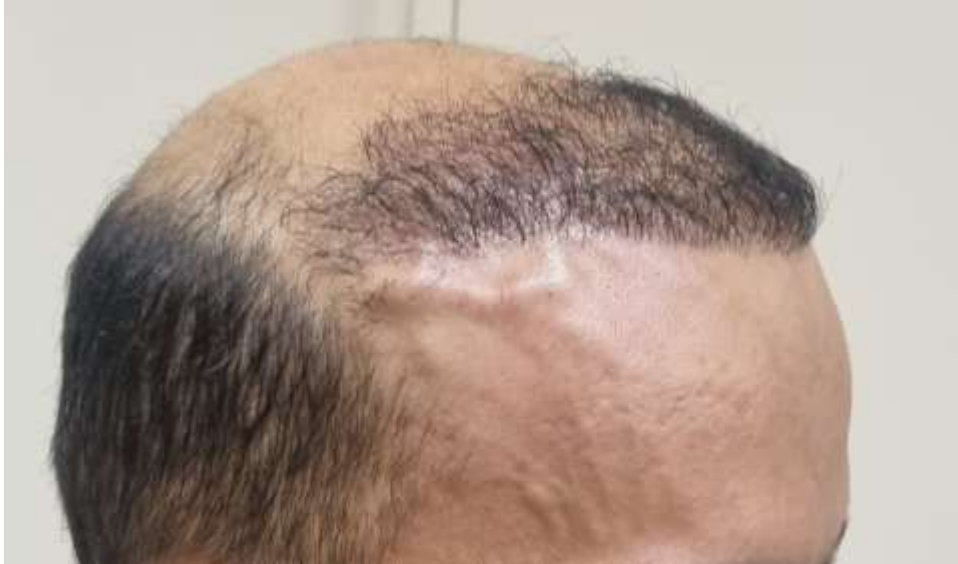**Figure 1:** Close-up scalp photograph of the patient demonstrating the dilated scalp arteries and draining veins.



**Figure 2:** CT angiography with 3D Volume-rendered image of the right parietal region AVF (Green arrow) with dilated and tortuous superficial temporal artery (Red arrows) and its branches with large draining veins (Blue arrows) New arrows added



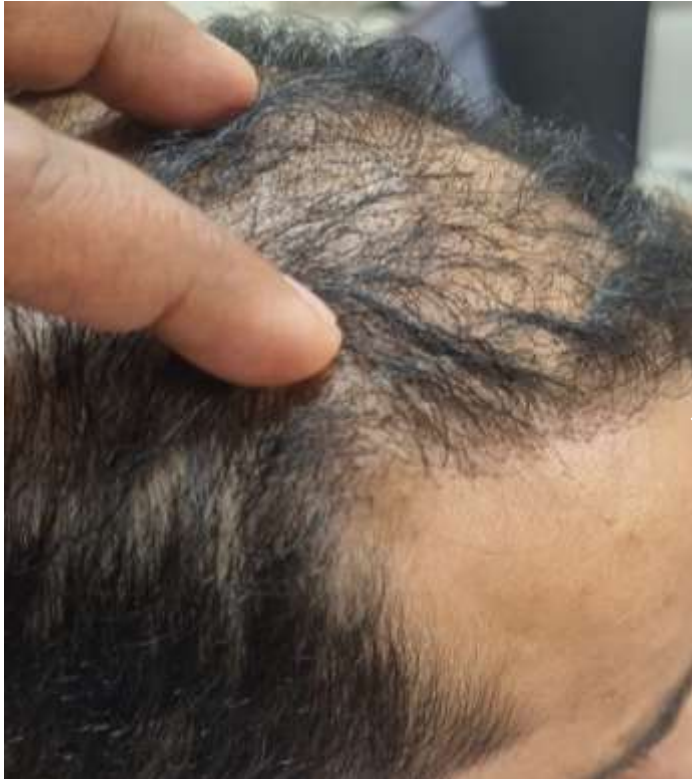**Figure 3:** a) Selective Digital subtraction angiography of the right external carotid artery shows abnormal dilated and tortuous superficial temporal (Red arrows) and occipital arteries (Yellow arrows) with arteriovenous fistula (Green Arrow) and multiple dilated early draining veins (Blue arrows). b) Fluoroscopy snapshot image shows multiple metallic coils in the superficial temporal artery (Red arrows) and the glue cast in the occipital artery (Yellow arrow)



**Figure 4:** Post intervention appearance

### ***Case two***

A 36-year-old gentleman with no previous medical or surgical background, not on any medications, presented with history of having had a pulsatile swelling on the right side of his forehead with on and off mild headache, following hair transplant. The symptoms began about two months after the transplant. He presented to the local hospital and was referred to our vascular team for management. Upon review at our OPD, six months thereafter, his symptoms had resolved and the swelling had reduced in size with no pulsation. Examination revealed a 0.5x0.5cm, mobile, firm scalp swelling in the frontal area with no skin changes, was non-tender and had no thrill/bruit or pulsations [Figure 5]. His CTA, done at the local hospital, confirmed a thrombosed iatrogenic scalp AVF not requiring any intervention. Patient was re-assured and discharged from the clinic.



**Figure 5:** Thrombosed Iatrogenic Scalp AVF

## Discussion

Scalp arteriovenous fistula is a rare abnormal fistulous communication which are either congenital or traumatic in origin. Iatrogenic injury following hair transplant is one of the extremely rare complications. Given its low incidence, limited data and there are few published case reports worldwide.<sup>1</sup>

Hair transplant is considered the most common cosmetic procedure for men. These procedures classically involve the resection of small patches of superficial skin containing hair follicles that are then implanted into a recipient site through an incision or punch insertion. Direct vascular injury due to punches, needles and/ or micro-blades result in the extremely rare scalp AVF.<sup>2</sup>

Most scalp AVFs following hair transplant originate from the superficial temporal artery likely due is superficial path over the temporal bone and its proximity to cranial sutures. Less common sites include occipital artery or both.<sup>3</sup>

Two mechanisms were suggested to explain the formation of an AVF following hair transplant. First when there is simultaneous laceration of the artery and the adjacent vein resulting in formation of the fistula. The other proposed mechanism when rupture of the vasa vasorum in the arterial wall occurs leading to proliferation of endothelial cells from the damaged vasa vasorum which then forms multiple small vessels creating an abnormal communication between artery and vein.<sup>4</sup>

Scalp AVF usually present months to years after hair transplant. Its clinical manifestation mainly painful pulsatile scalp swelling, however few patients reported headaches, tinnitus and rarely patients presented with seizures. Physical examination often reveals dilated scalp veins with pulsations. In terms of diagnosis, angiography remains the gold standard.<sup>5</sup>

Few published reports have explored the clinical presentation, treatments, and outcomes related to iatrogenic AVFs. José et al. reported a case of a traumatic AVF treated with a PHIL embolic agent after capillary implantation, emphasizing on the effectiveness of embolization as a less invasive treatment option.<sup>1</sup> Moreover, Ki et al. also reviewed post-traumatic AVFs highlighting the need for early diagnosis and treatment to prevent complications like bleeding or scarring.<sup>3</sup> Finally Zheng et al. compared intravascular embolization with surgical resection and found that both methods can work well, with preference to embolization giving it is less invasive and comes with fewer risks<sup>6</sup>

Treatment options for scalp AVF post hair transplant include surgical excision, endovascular therapy or combined. Due to its rarity and limited data, there is currently no established consensus on treatment strategies. The current published available data supports endovascular approach due to its advantages of being less invasive and carries less complications risk. Moreover, endovascular is both diagnostic and therapeutic. Endovascular options include transarterial or percutaneous embolization using coils or liquid embolic agents like Onyx.

## Conclusion

While uncommon, when patients exhibit pulsatile swelling after hair transplant surgery, considering arteriovenous fistula as a potential diagnosis is prudent. Fortunately, various treatment options exist for this condition, making it manageable

## Disclosure

No conflict of interests

## Acknowledgment

Both patients have given a written consent of publication of their clinical and radiological images

## References

1. Alfaro AJ, Ortíz AF, Mejía JA, Ortegón JD, Gutiérrez LC, Tovar CA, et al. Traumatic scalp arteriovenous fistula post capillary implantation successfully treated using PHIL embolic agent. *Surg Neurol Int* 2023 Jan;14:12-2.
2. Jason IL, Timur U, Brian S, Eric CP. Scalp Arteriovenous Fistula following Hair Transplantation: A Case Report and Review of the Literature. *Clin Med Rev Case Rep* 2018 Feb;5(2).
3. Ki HJ, Lee HK, Hur JW, Lee JW. Post-Traumatic Arteriovenous Fistula of the Scalp. *J Korean Neurosurg Soc* 2015 Sep;58(3):298-300.
4. de O. Fayad M, Guilherme, Sthefano Atique Gabriel, Maria I. Traumatic arteriovenous fistula of the superficial temporal artery. *J Vasc Bras* 2014 Mar;13(1):39-42.
5. Biegaj E, Rutkowska-Zimirska J, Radzymińska-Maliszewska M, Zaremba A, Pniewski J. Arteriovenous fistula of superficial temporal vessels. *Folia Morphol (Warsz)* 2019;78(4):879-882.
6. Zheng J, Guo Z, Zhang X, Sun X. Intravascular embolization versus surgical resection for patients with scalp arteriovenous fistula. *Chin Neurosurg J* 2019 Jan;5(1):3.