

A Case of Puerperal Pulmonary Embolism

Reshma VP Nair^{1*} and Rajeev Chatanath²

¹Department of Obstetrics and Gynecology, NMC Speciality Hospital, Muscat, Oman

²Department of Internal Medicine, NMC Speciality Hospital, Muscat, Oman

Received: 15 December 2023

Accepted: 22 February 2024

*Corresponding author: reshmavp0@gmail.com

DOI 10.5001/omj.2026.26

Abstract

Venous thromboembolism (VTE) is a leading cause of direct maternal death. We present a case of a woman who developed puerperal pulmonary embolism on the sixth day after an emergency caesarean section. The patient had a history of anemia. Her pulmonary embolism was initially treated with low molecular weight heparin overlapped with warfarin. However, the desired international normalized ratio (INR) was not achieved. Hence, after ensuring that she was not breast feeding, rivaroxaban, a novel direct oral anticoagulant (DOAC), was started. Her condition improved, symptomatically and radiologically. While on rivaroxaban, lupus anticoagulant positivity was observed, which resolved as soon as rivaroxaban therapy ended. More randomized control trials are needed regarding safety of rivaroxaban during the puerperium period.

Keywords: Pulmonary Embolism; Venous Thromboembolism; Puerperium Anticoagulants; Warfarin; Heparin; Oman

Introduction

Venous thromboembolism (VTE) remains one of the leading causes of direct maternal death. Puerperium is the time of highest risk.¹ During pregnancy and puerperium, VTE can also be one of the presenting features of antiphospholipid antibody (APLA) syndrome, which can give rise to diagnostic and therapeutic challenges.

Case Report

Our patient was a 33-year-old mother of two children, both born by emergency caesarean section. Six days after her second caesarean operation, she presented with increasing breathlessness since post-partum day-4, orthopnea, and an atypical chest pain.

From the fifth month of pregnancy, she developed nutritional iron deficiency and was prescribed iron supplements. She was admitted with labor pains on the 38th week. During admission, there was single recording of high blood pressure with no further symptoms. The blood results were normal except for low hemoglobin (10 g/dL). Due to fetal distress, an emergency caesarean section was conducted. No intraoperative or post-operative complications were identified. Intraoperative blood loss was about 200 mL. As the patient was ambulant, she was discharged on post-natal day 3 on oral antibiotics, low molecular weight heparin, and hematinics.

On the current presentation, she was found to have high blood pressure (160/90 mm Hg) which was treated with amlodipine. Her chest was clear and oxygen saturation normal. Electrocardiogram (ECG) and chest X Ray were also normal. Troponin-I was negative and echocardiogram (echo) showed mild to moderate pulmonary hypertension with

normal biventricular function. Computed tomography pulmonary angiogram (CTPA) was done as ventilation perfusion scan (V/Q) was not available. The CTPA image showed thrombus 1.6 × 1 cm in the left inferior lobar pulmonary artery extending to the left inferior lobar segmental branches [Figure1]. Venous Doppler images of both lower limbs were normal.

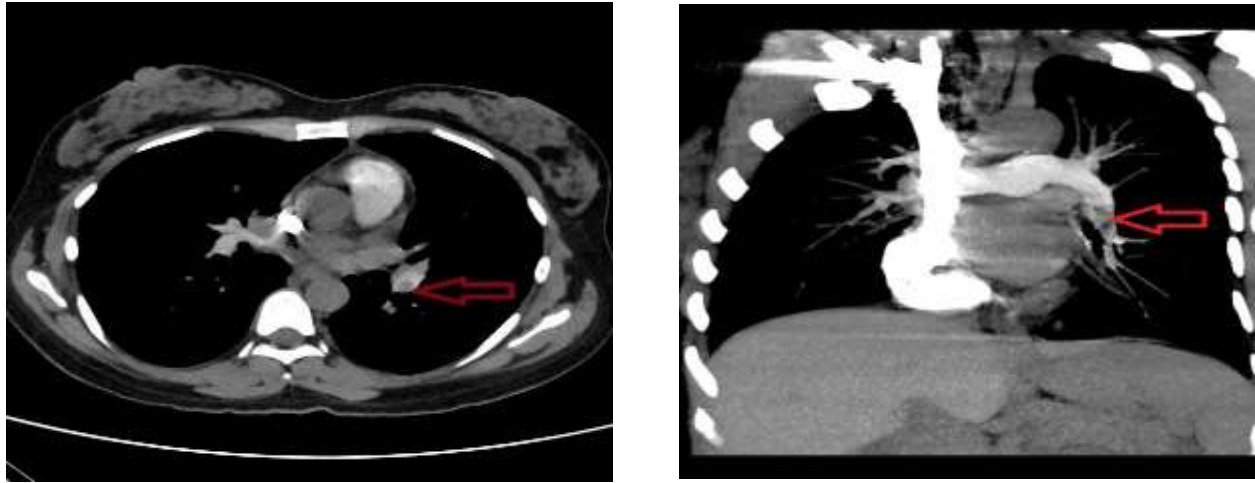


Figure 1: (a) Axial section of computed tomography pulmonary angiogram (CTPA) showing thrombus in left inferior lobar pulmonary artery (arrow). (b) Maximum intensity projection (MIP) image of the coronal section showing filling defect in left inferior pulmonary artery (arrow).

The patient was given low molecular weight heparin 80 mg twice daily (based on body weight) overlapped with warfarin 5 mg. As the INR was persistently staying at 1.1, the warfarin dose was increased to 10 mg and later to 15 mg. Patient had stopped breast feeding as the baby was refusing to suck breast. As the baby was not being breastfed, it was possible to initiate rivaroxaban, a novel direct oral anticoagulant (DOAC), at a dose of 15mg twice daily. As rivaroxaban is contraindicated during breastfeeding, the patient was cautioned in advance against resuming breastfeeding.

A repeat echo after 25 days of rivaroxaban therapy (45th day post-partum) showed no pulmonary artery hypertension and normal left ventricular function. Rivaroxaban 15 mg twice daily was continued for three more weeks and thereafter reduced to 20 mg once daily. On 53rd day of post-partum, antiphospholipid antibody (APLA) testing was done following positive result of ANA. The APLA results were positive for lupus anticoagulant and anti DsDNA. After three months of the first test (two weeks after stopping rivaroxaban) the APLA testing was repeated. This time the results were negative. Thus, the patient recovered, symptomatically and radiologically, following rivaroxaban therapy over a period of 121 days, from post-partum day 21 to 156 [Table 1].

Table 1: The schedule and dosage of rivaroxaban therapy.

Post-partum days	Dosage
21–45 (25 days)	15 mg twice daily
46–66 (21 days)	15 mg twice daily
67–156 (3 months)	20 mg once daily

Discussion

The absolute incidence of venous VTE in pregnant women has been reported to be about 1 in 1000.¹ Pregnant women are approximately five times more likely to experience VTE than non-pregnant women, and this risk is estimated to increase to about twenty-fold in puerperal women.^{1,2}

The risk factors for VTE are several, including pre-existing, obstetric, and transient ones. In the current case, the possible triggers were the emergency cesarean section and the preexisting nutritional anemia. Even though clinical examination, ECG, chest X ray yielded normal results, a high index of suspicion of VTE and worsening of symptoms helped in clinching the diagnosis.

The APLA syndrome is one of the acquired thrombophilia syndromes leading to arterial, venous, or micro vascular thrombosis or obstetric morbidities due to the presence of persistent antiphospholipid antibodies. As per the revised Sapparo criteria,³ a diagnosis of APLA syndrome requires one clinical and one laboratory parameter to be positive. Antibodies need to be retested after 12 weeks to confirm the diagnosis. In the current case, even though initially lupus anticoagulant was positive while on DOAC, it became negative after three months (after stopping DOAC for two weeks). Therefore, APLA syndrome was ruled out as a cause for pulmonary embolism. The literature also suggests the possibility of lupus anticoagulant showing ‘false positive’ while on DOAC.⁴

The treatment of pulmonary embolism involves using low molecular weight heparin dose titrated according to the body weight. Accordingly, our patient was given heparin 80 mg twice daily. In view of the difficulty of giving daily injections, heparin was overlapped with oral warfarin. However, even with 15 mg warfarin, desired INR was not achieved. A case control study⁵ regarding warfarin dosage in post-partum period reports significantly higher doses for longer periods as being necessary to reach the desired INR. In our patient, the lack of effectiveness of warfarin might have been due to altered coagulation parameters in pregnancy continuing into the puerperium. Therefore, we switched to rivaroxaban, a novel DOAC, whose advantages include fixed doses, no requirement of monitoring anticoagulant effect, simplified preoperative management, reduction of major intracranial bleeding, and fewer food drug interactions.

However, clinicians need to be aware that the latest Green Top guidelines by the Royal College of Obstetricians & Gynecologists^{6,7} do not recommend DOAC use in pregnancy or non-lactating women. Also, no guidance has been issued on DOAC use in post-partum non-breastfeeding women such as our patient. This may be because no randomized controlled trials (RCTS) have been conducted on the effect of DOACs on pregnant and lactating mothers, fetuses, and neonates. We chose rivaroxaban treatment because the traditional anticoagulants were not effective and after our literature search yielded a few new case reports endorsing the benefits of DOAC in post-partum period.⁸

Conclusion

High index of suspicion is required in any post-partum patient presenting with symptoms of breathlessness. More RCTS and individual case reports are needed regarding the use of direct thrombin inhibitors during puerperium in both lactating and non-lactating mothers. Additionally, more research is required on positivity of lupus anticoagulant and single antibody thrombotic APS reported in some patients on DOAC.

Disclosure

The authors declare no conflicts of interest. Informed written consent was obtained from the patient and her relative.

References

1. Jacobsen AF, Skjeldestad FE, Sandset PM. Incidence and risk patterns of venous thromboembolism in pregnancy and puerperium—a register-based case-control study. *Am J Obstet Gynecol* 2008;198:233.e1-233.e7.
2. Jackson E, Curtis KM, Gaffield ME. Risk of venous thromboembolism during the postpartum period: a systematic review. *Obstet Gynecol* 2011 Mar;117(3):691-703.
3. Miyakis S, Lockshin MD, Atsumi T, Branch DW, Brey RL, Cervera RH, et al. International consensus statement on an update of the classification criteria for definite antiphospholipid syndrome (APS). *J Thromb Haemost* 2006;4(2):295-306.
4. Arachchillage DR, Laffan M. What is the appropriate anticoagulation strategy for thrombotic antiphospholipid syndrome? *Br J Haematol* 2020 Apr;189(2):216-227.

5. Brooks C, Rutherford JM, Gould J, Ramsay MM, James DK. Warfarin dosage in postpartum women: a case-control study. *BJOG* 2002 Feb;109(2):187-190.
6. Royal College of Obstetricians and Gynaecologists. Reducing the risk of thrombosis and embolism during pregnancy and the puerperium (Green-top Guideline No. 37a). 2015 [cited 2024 March 29]. Available from: <https://www.rcog.org.uk/guidance/browse-all-guidance/green-top-guidelines/reducing-the-risk-of-thrombosis-and-embolism-during-pregnancy-and-the-puerperium-green-top-guideline-no-37a/>.
7. Royal College of Obstetricians and Gynaecologists. Thrombosis and embolism during pregnancy and the puerperium: acute management (Green-top Guideline No. 37b). 2015 [cited 2024 March 29]. Available from: <https://www.rcog.org.uk/guidance/browse-all-guidance/green-top-guidelines/thrombosis-and-embolism-during-pregnancy-and-the-puerperium-acute-management-green-top-guideline-no-37b/>.
8. Muysson M, Marshall K, Datta P, Rewers-Felkins K, Baker T, Hale TW. Rivaroxaban treatment in two breastfeeding mothers: a case series. *Breastfeeding Medicine* 2020 Jan 1;15(1):41-43.