

Floating Debris Sign: A Helpful Diagnostic MRI Sign of Fat-Free Mature Cystic Teratoma - A Case Report and Review of the Literature

Hajar Al Saadi^{1*}, Ishaq Al Salmi², Sara Alamrani¹, Kawther Al Rashdi³ and Atheel Kamoona²

¹Radiology Residency Training Program, Oman Medical Specialty Board, Muscat, Oman

²Radiology Department, Royal Hospital, Muscat, Oman

³Anesthesia Residency Training Program, Oman Medical Specialty Board, Muscat, Oman

Received: 16 October 2023

Accepted: 4 January 2024

*Corresponding author: hajaralsaadi55@gmail.com

DOI 10.5001/omj.2026.13

Abstract

Ovarian teratoma is a type of germ cell tumor derived from one or more of the three germ cell layers. It can be mature cystic teratoma (MCT), commonly referred to as a dermoid cyst, or immature teratoma. Most MCT can be differentiated from immature teratoma through MRI due to their fat content showing typical features that are identified by fat suppression sequences. We present a case of a fat-free ovarian dermoid cyst in a 21-year-old female with an abdominal mass that was diagnosed with bilateral MCT on pathology, although the diagnosis on MRI was not straightforward due to a lack of fat within one of the masses. We describe additional MRI clues to the diagnosis of fat-free dermoid cyst in our case, aiming for better characterization in similar cases in the future.

Keywords: Mature Cystic Treating; MRI; Floating Debris; Ovarian Tumor.

Introduction

Ovarian teratoma is the most common germ cell tumor, representing 20% of all ovarian neoplasms. Ovarian teratomas are further sub-categories as mature cystic teratomas, immature teratomas, monodermal teratomas, and fetiform teratomas.¹ The most common is mature cystic teratoma (MCT). Clinically, patients with teratoma can be asymptomatic or have minimal symptoms such as lower abdominal pain, pelvic mass, or the patient may present with a picture of a cystic teratoma complicated by ovarian torsion.²

MCT can be easily identified through radiological imaging, with US being the preferred initial investigation. US shows a heterogeneous appearance characterized by echogenic sebaceous material and calcifications demonstrating acoustic shadowing.

CT and MRI have high sensitivity in diagnosing MCT through the detection of fat within the mass as well as calcifications. On MRI, the fat demonstrates high signal intensity on T1-weighted images with signal drop on fat-saturated T1-weighted images.¹

While immature teratoma has a nonspecific appearance in US, mainly showing heterogeneous components, partially solid with calcifications. On CT and MRI, immature teratoma demonstrates large irregular solid components with coarse calcification with no suppression on fat-suppression sequence.³

Case Report

A 21-year-old young unmarried lady with no known medical background presented in 2010 with a pelvic mass. She noticed abdominal distention three weeks prior, associated with mild lower abdominal pain and no constitutional symptoms. She has no menstrual abnormality. On abdominal examination, the mass was palpable, 20 weeks gravid uterine size, non-tender and non-mobile. Tumor markers were all within normal levels except cancer antigen-125 (CA-125) which was mildly raised at 146 IU/mL (0–35 IU/mL).

MRI showed a well-defined oval cystic mass, related to the left ovary, measuring $13.3 \times 11.4 \times 9.5$ cm, predominantly hyperintense on T1- and T2-weighted images, showing no suppression on fat-suppression sequences, denoting the presence of high proteinaceous content or blood. It contained innumerable variably sized and shaped floating debris distributed throughout the cystic mass, most of them are hypointense on both T1- and T2-weighted images, and the large ones are hyperintense on T2 and isointense on T1-weighted images [Figure 1]. No abnormal enhancement was seen in the post-contrast study. Those findings were favored to represent a teratodermoid tumor, likely benign in origin. In addition, the MRI also demonstrated another well-defined small right heterogeneous ovarian lesion, measuring 2.5 cm in diameter, which was predominantly hyperintense on T2- and T1-weighted images, showing signal drop-out on the fat-suppression sequences, denoting the presence of fat, suggestive of a dermoid cyst. The uterus appeared normal.

The patient underwent laparotomy, left salpingo-oophorectomy, right ovarian cystectomy with peritoneal biopsies. Histological examination showed a large $14 \times 10 \times 6$ cm left ovarian cystic mass weighing 820 g. The cyst was filled with thick creamy keratinous material and scanty hair. No other solid areas were identified. The right ovarian cyst measuring $2.5 \times 2.0 \times 2.0$ cm contained friable cheesy material and hair.

On microscopy, the cysts showed fibrous walls lined partly by squamous epithelium and partially by respiratory-type epithelium. The epithelium exhibits areas of ulceration with subjacent granulation tissue and a lympho-histiocytic cell infiltrate. The wall contains smooth muscle fibers, scattered lymphocytes, and pigment epithelium. Scanty glial tissue was seen.

The ovarian stroma showed a follicular cyst. No immature elements were present, and sections from the fallopian tube showed unremarkable morphology.

In 2018, the patient had multiple visits to the emergency room with lower abdominal pain. MRI was done three times; in 2018, 2019 and 2022, showing three subjacent fat-containing cystic masses in the right ovary, which were gradually increasing in size. Last sizes noted up to $4.4 \times 3.6 \times 3.5$ cm, $2.5 \times 2.4 \times 1.8$ cm and $2.5 \times 2.4 \times 1.8$ cm, respectively, suggestive of subjacent dermoid cysts. Based on those findings, she was planned for surgery in 2022, but she was lost to follow-up.

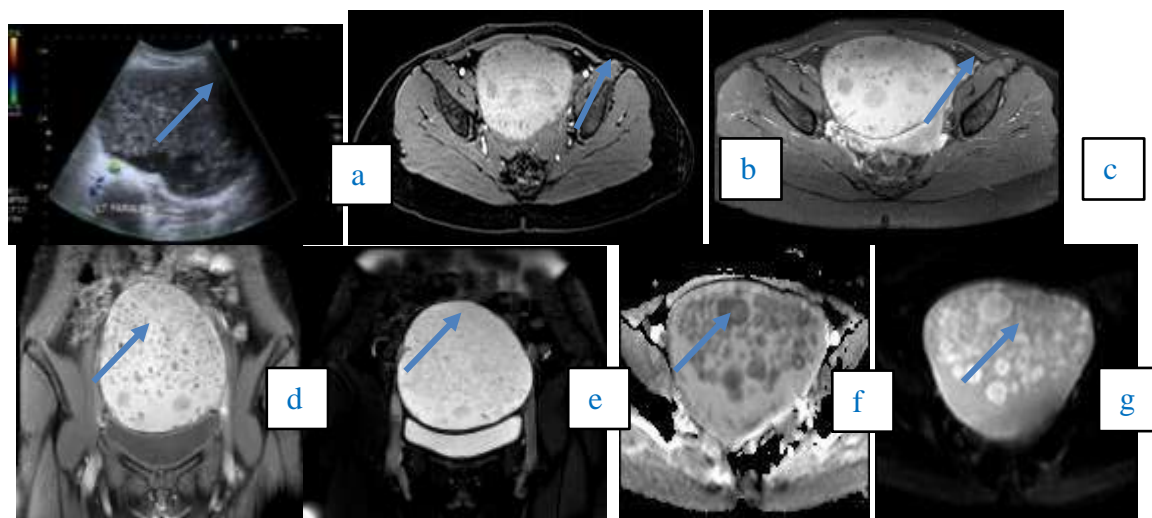


Figure 1: Grey-scale US image (a) showing a large complex (cystic and solid), avascular left adnexal mass with multiple internal echogenic foci. MRI axial T1WI (b) pre- and (c) post-contrast showing a non-enhancing predominantly high T1 signal lesion with innumerable variably sized and shaped floating debris contents which are hypointense on both T1 and T2-weighted imaging. (d) Coronal T2-weighted imaging and (e) T2 fat suppression shows predominantly high T2 signal with no suppression on fat suppressed sequence. There is no diffusion restriction in (f) diffusion-weighted-imaging (DWI) and (g) apparent-diffusion coefficient (ADC) map.

Discussion

The fatty component of MCT is the primary diagnostic feature identified through MRI; however, studies have shown that a small percentage of MCT can present with minimal or no fat in the cyst. In one case series study done in Japan by Yamashita et al.,⁴ which included 78 cases, 12 of them had no fat component on pathology review and five of those showed no fat suppression on MRI. In this case series, they suggested the use of gradient-echo MRI.⁴

Another study in Saudi Arabia of a 19-year-old female with fat free MCT showed that there are atypical areas of fat within the mass, like fat in the wall which is described in their study. However, no other signs were mentioned to reach the diagnosis by imaging.⁵ In our case, we emphasize the use of an additional sign which can help in diagnosing fat free MCT. This sign is the presence of non-enhancing variable-sized and variable-shaped floating debris at different levels within the cystic mass. In the literature, it is referred to as a floating balls sign. Floating ball sign is a known pathognomonic sign of MCT which appears as floating globules within the cyst independent of gravity, usually this sign appears to be hypointense on T1-weighted and hyperintense on T2¹ in contrast to its appearance in our case.

A case by Kawamoto et al.,⁶ presented a similar finding of floating spherical shaped debris in MCT that has no fat on pathological examination. In their case, the MRI sagittal T1-weighted images demonstrated an area at the outer portion of the spherical structure of slightly hyperintense signal relative to the surrounding fluid, but not as hyperintense as subcutaneous fat. The center of the spherical structure was relatively hypointense compared with the outer portion. There was a fluid debris level in the dependent portion of the cystic mass. On sagittal and coronal T2-weighted images, the outer portion of the spherical structure was hypointense, and the center relatively hyperintense.⁶

Also, Esphidola et al., described a similar finding in their case of multiple small floating spheres within a large cyst on MRI, the oval formations showed intermediate signal intensity on T1- and T2-weighted images, with no evidence of signal loss in fat-saturated sequences.⁷

Both cases matched the findings in our case with a slight difference in the shapes of the floating materials. In our case, it is more heterogeneous with linear, oval and spherical shaped floating debris that were hypointense on both T1 and T2 weighted images and the large ones are hyperintense on T2 and isointense on T1 weighted images. The second difference is the distribution of the debris which is throughout in our case while it was more in the independent half of the cyst in the previously published cases.

A retrospective study was done by Şahin et al.,⁸ regarding the utility of floating balls sign in diagnosing MCT. The study included 112 MCT with floating ball sign in which only one lesion had floating balls sign and was fat free in both radiology and pathology results. The study result showed that this sign has a rather high incidence rate of 25%, is more associated with large MCT and can be seen in both benign and malignant MCT.⁸

Conclusion

The atypical presentation of fat free MCT should be recognized by radiologists including the presence of floating debris sign without fat suppression of the lesion on pelvis MRI. Although rare, the presence of this sign does not exclude the possibility of malignant degeneration into squamous cell carcinoma and therefore assessment for enhancing soft tissue components is important.

Disclosure

The authors declare no conflicts of interest. Informed consent was obtained from the patient.

References

1. Sahin H, Abdullazade S, Sancı M. Mature cystic teratoma of the ovary: a cutting edge overview on imaging features. *Insights Imaging* 2017 Apr;8(2):227-241.
2. Ayhan A, Bukulmez O, Genc C, Karamursel BS, Ayhan A. Mature cystic teratomas of the ovary: case series from one institution over 34 years. *Eur J Obstet Gynecol Reprod Biol* 2000 Feb;88(2):153-157.
3. Outwater EK, Siegelman ES, Hunt JL. Ovarian teratomas: tumor types and imaging characteristics. *Radiographics* 2001;21(2):475-490.
4. Yamashita Y, Hatanaka Y, Torashima M, Takahashi M, Miyazaki K, Okamura H. Mature cystic teratomas of the ovary without fat in the cystic cavity: MR features in 12 cases. *AJR Am J Roentgenol* 1994 Sep;163(3):613-616.
5. AlGhamdi M, AlMutairi B, AlOsaimi A, Felemban A, AlYahya M. Mature cystic ovarian teratoma without intracystic fat: case report with the "fat within the wall" sign. *Radiol Case Rep* 2020 Feb;15(4):367-370.
6. Kawamoto S, Sato K, Matsumoto H, Togo Y, Ueda Y, Tanaka J, et al. Multiple mobile spherules in mature cystic teratoma of the ovary. *AJR Am J Roentgenol* 2001 Jun;176(6):1455-1457.
7. Espindola AP, Amorim VB, Koch HA, Bahia PR, Almeida MV. Atypical presentation of mature cystic teratoma ("floating balls"). *Radiol Bras* 2017;50(3):206-207.
8. Şahin H, Akdoğan AI, Ayaz D, Karadeniz T, Sancı M. Utility of the "floating ball sign" in diagnosis of ovarian cystic teratoma. *Turk J Obstet Gynecol* 2019 Jun;16(2):118-123.