

Retinal Dystrophy and Leukodystrophy Caused by ACBD5 deficiency in Five Omani Patients: A Case Series

Bushra Al Shamsi¹, Anuradha Ganesh², Beena Harikrishna², Sana Al Zuhaibi², Ivana Markovic³, Ahmed Mansy⁴, Khalid Al Thihli¹, Faraz Ahmad⁴, Maha Mameesh² and Fathiya Al Murshedi^{1*}

¹Genetic and Developmental Medicine Clinic, Department of Genetics, Sultan Qaboos University Hospital, Muscat, Oman

²Department of Ophthalmology, Sultan Qaboos University Hospital, Muscat, Oman

³Department of Radiology and Molecular Imaging, Sultan Qaboos University Hospital, Muscat, Oman

⁴Department of Child Health, Sultan Qaboos University Hospital, Muscat, Oman

Received: 15 August 2023

Accepted: 8 October 2023

*Corresponding author: murshedi@squ.edu.om

DOI 10.5001/omj.2025.34

Abstract

Acyl-coenzymeA-binding domain-containing protein 5 (ACBD5) is an acyl-CoA-binding peroxisomal membrane protein. Its deficiency impairs peroxisomal beta-oxidation of very long chain fatty acids (VLCFAs) and leads to an autosomal recessive disorder, manifesting mainly as retinal dystrophy and leukodystrophy. We report five Omani patients with ages ranging between 4 and 30 years. First presentation was in infancy with nystagmus and photophobia and progressed to legal blindness by 10 years of age. Electroretinogram (ERG) confirmed severe cone-rod dystrophy. Motor neuroregression with variable ages of onset and signs of progressive cerebellar ataxia were seen in all whereas cognitive decline was observed in some. Brain MRI revealed diffuse T2 signal abnormality in deep white matter with involvement of corticospinal tracts. Plasma VLCFA profile showed mild elevation of C26 and C26/22 ratio. Two homozygous variants in *ACBD5* gene were identified; exons 7 and 8 deletion and exon 4 deletion. This series confirms retinal dystrophy and leukodystrophy as key features of *ACBD5* deficiency with main symptoms of early onset visual decline, progressive spasticity, and cerebellar ataxia. This case series is valuable in adding to the understanding of this ultra-rare neurometabolic disease.

Keywords: Cone-Rod Dystrophy; Ataxia; Spastic Paraplegia; *ACBD5*; Peroxisomal Disorder; Oman

Introduction

Defects in human genes encoding peroxisomal proteins can result in different peroxisomal disorders with variable severity ranging from early lethality to subtle neurosensory abnormalities.¹ acyl-CoA-binding domain-containing protein 5 (ACBD5) is a peroxisomal membrane protein with a C-terminal membrane-spanning region and an N-terminal cytosolic acyl-CoA binding domain. It is postulated to function as a peroxisomal membrane-bound receptor for very long chain fatty acids (VLCFA) facilitating their transport into the peroxisome and subsequent β -oxidation.^{2,3} The absence of ACBD5 in human skin fibroblasts did not affect the biogenesis of peroxisomes, but impaired peroxisomal beta-oxidation of VLCFA leading to elevation of the level of cellular phospholipids containing VLCFA without affecting peroxisomal biogenesis.^{3,4}

The first time a biallelic pathogenic variant in the *ACBD5* gene described to be associated with retinal dystrophy and leukodystrophy was in 2013, in three siblings from a consanguineous Saudi Arabian family.⁵ In 2017, Ferdinandusse et al described a nine-year-old girl from the United Arab Emirates (UAE) who had retinal dystrophy, leukodystrophy in addition to cleft palate and facial dysmorphism.³ In 2021, a 36-year-old Brazilian woman was described with retinal dystrophy, leukodystrophy, and psychomotor regression.⁶ The seventh and last available report of this condition featured two Turkish sisters aged five and nine years with early onset nystagmus, progressive motor decline and ataxia.⁷

This case series presents five Omani patients from four families to further emphasize the consistent clinical, radiological, and biochemical findings and expand the phenotypic spectrum of this relatively newly recognized disorder.

Case Reports

Case one (Male, 10 y)

This Omani boy is the eldest child of a non-consanguineous Omani couple. He was noted to have nystagmus at three months of age and spasticity at 14 months. Ophthalmic examination revealed horizontal and pendular nystagmus, sensitivity to light, severe visual impairment in both eyes, and mild compound myopic astigmatism. Fundus examination showed pale discs with attenuated vessels and pigmentary changes at the macula which progressed to atrophy with mild tessellation of the background retina. Electroretinogram (ERG) showed severe cone-rod dysfunction. Very long chain fatty acids (VLCFA) profiling showed elevated C26:0 (1.36 $\mu\text{mol/L}$, normal 0.23 \pm 0.09) and C26:0/C22:0 ratio 0.27 (0.01-0.004) along with elevated pristanic and phytanic acids suggestive of a peroxisomal disorder. Other investigations included normal echocardiography and nerve conduction study (NCS). Intelligence Quotient (IQ) test by Stanford Binet 5th edition at the age of six years showed a total IQ of 65 corresponding to mild intellectual disability. Brain magnetic resonance imaging (MRI) showed demyelinated periventricular and deep white matter [Table 1, Figure 1: A, B, C, D, E, F]. Whole Exome Sequencing (WES) of his younger affected sibling (Case 2) identified a homozygous deletion in exons 7 and 8 of the *ACBD5* gene. Upon assessment at the age of ten years, the patient had worsening mobility, intention tremor, and scanning speech. He was wheelchair-bound and was able to type with great difficulty. He had full bladder and bowel control. He was microcephalic (head circumference at -3.6SD) with weight and height below the 2nd percentile as well (both at -2.7SD). Neurological examination was remarkable for central hypotonia, severe lower limb spasticity and scissoring, ankle joint contractures, and brisk deep tendon reflexes.

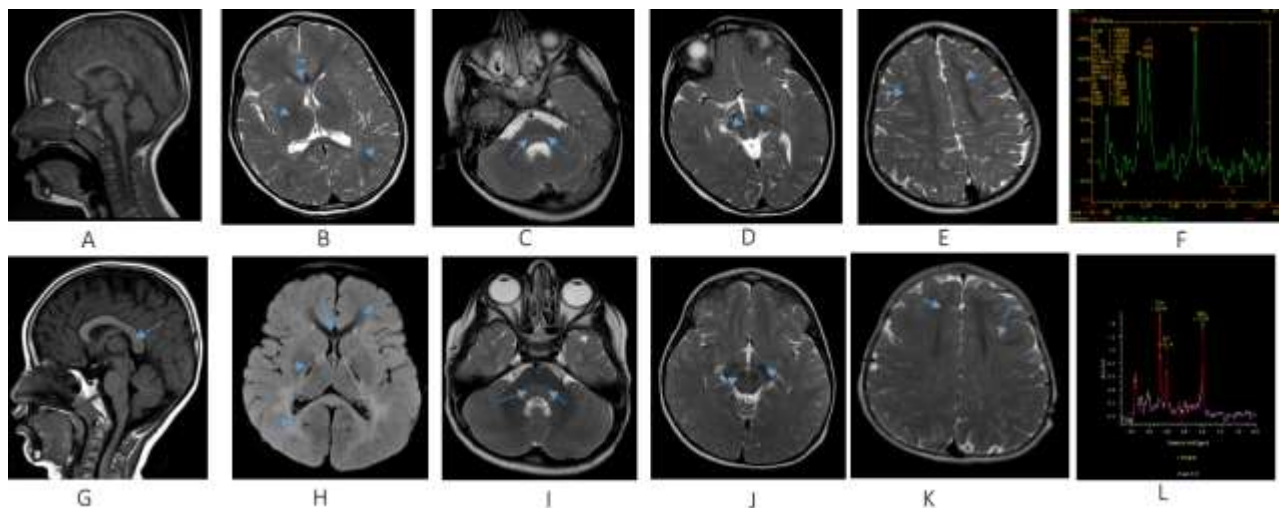


Figure 1: A–F: Comparative MRI brain of Patient 1 obtained at age of 4 years. G–L: MR brain of his brother years old (Patient 2) obtained at age of 3 years: sagittal T1W (A,G), axial FLAIR (H), axial SE T2W (B, C, D, E, I, J, K) images and MR (F, L) showing diffusely altered hypomyelinated/demyelinated periventricular and deep white matter with posterior pattern due to dominant involvement of parietal and occipital lobes (B, H), splenium corpus callosum (B, G, H) and posterior pontine tegmentum (C, I); visible residual preserved hypointense myelinated white matter at frontal lobes (E, K), also with sparing subcortical fibers (E, K) and genu of corpus callosum (B, H); consequent striking appearance of posterior limb of internal capsule (B, H), substantia nigra and red nuclei in midbrain (D, J) and medial lemniscus identified as hypointense dots in posterior pontine tegmentum (C, I); MR spectroscopy correlates with metabolic disorder presenting in Case 1 with moderately decreased N acetylaspartate (NAA) and increased choline (F) and more significantly lower NAA and elevated Choline in Case 2 (L); all described structures are marked with arrows on mentioned images.

Case two (Male, 4 y)

The patient, the younger brother of the patient at Case 1, had nystagmus and photosensitivity when five months old. Even though at 15 months he had begun to walk independently, by the age of three years his gait rapidly

became unsteady, followed by a complete inability to walk unassisted. His speech progressed well in the first two years but regressed thereafter.

At the age of four, the child's head circumference was at 10th percentile, weight at 8th percentile and height at 2nd percentile. Physical examination revealed head titubation with intention tremor, hypotonia with hyperextensible large joints, contractures in Achilles' tendons bilaterally, and brisk deep tendon reflexes. Visual evoked potential (VEP) yielded no response in the right eye and normal response in the left eye. Ophthalmic examination showed nystagmus, photosensitivity, severe visual impairment, mild mixed astigmatism, pale discs, attenuated vessels, and a dull foveal reflex in both eyes. ERG showed severe cone-rod dysfunction. Brain MRI/MRS features as detailed in Table 1 [Figure 2: G, H, I, J, K, L]. WES (Centogene, Rostock, Germany) revealed a homozygous deletion by CNV analysis in exons 7 and 8 of the *ACBD5* gene.

Case three (female, 7 y)

This patient was the second-born to a first-cousin couple. Her history included nystagmus and photophobia at the age of five months, and lower limb spasticity was noted at 11 months when she started to pull to stand. Brain MRI at the age of three years showed bilateral signal abnormalities of deep white matter, mainly involving the posterior limb of the internal capsule and splenium.

At current presentation (seven years old), all her growth parameters were below the second percentile with weight at -4.8 SD, height at -4.5 SD, and head circumference at -3 SD. She was cruising and crawling around furniture but was unable to take independent steps. Despite clear speech, she showed significant learning disability. Neurological examination revealed upper limb hypertonia, severe lower limb spasticity, hyperreflexia, and extensor plantar response bilaterally. There was no intention tremor or dysarthria.

Ophthalmic examination was positive for nystagmus, photosensitivity, moderate myopic astigmatism, and severe visual impairment. Fundus examination revealed disc pallor, attenuated vessels, and mild granularity of the background retina with pigmentary changes at the macula, which progressed to an atrophic macula. VEP showed significant delayed P2 latency and severely reduced P2 amplitude, indicating severe nerve fibre loss. ERG revealed severe cone-rod dysfunction. VLCFA profile showed elevated C24:0 at 84.25 $\mu\text{mol/L}$ (18.99–72.54) and C26:0 at 1.71 $\mu\text{mol/L}$ (0.00–1.08). However, the C26:0/C22 and C26:0/C24:0 ratios were normal, as was the level of phytanic acid. Retinal dystrophy gene panel (Manchester University, NHS Foundation Trust, Manchester, UK) revealed a homozygous deletion of exons 7 and 8 of the *ACBD5* gene.

Case four (female, 10 y)

The eldest offspring of double-first-cousin parents, this patient's history included horizontal nystagmus and photophobia at the age of three months. She attained independent walking at the age of 13 months but by the age of 2 years, she was found to have gait unsteadiness, intention tremors, and lower limb hyperreflexia. By the age of three, her gait worsened with frequent falling and eventually progressed to limited independent walking and severely spastic gait. At the age of ten years, she continued to have poor school performance. Her weight, height, and head circumference ranged between 5th and 10th percentiles. Neurological examination revealed intention tremors, lower limb spasticity, and generalized hyperreflexia with bilateral ankle clonus. Ophthalmic examination results included severe visual impairment, pale optic discs, attenuated retinal arterioles, dull foveal reflexes, and pigmentary retinopathy [Figure 2]. ERG confirmed severe cone-rod dystrophy.

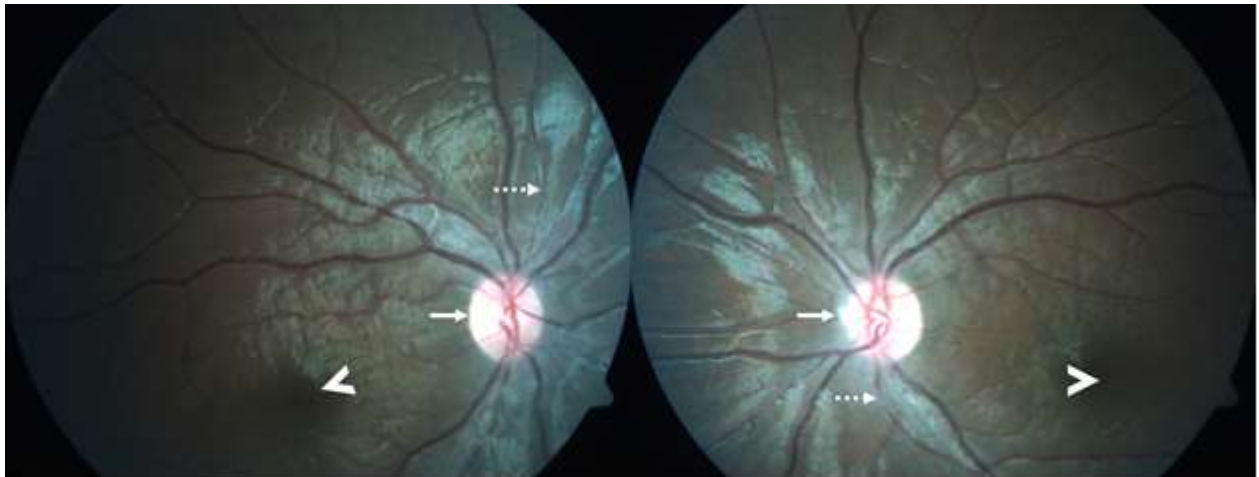


Figure 2: Fundus photographs (Case 4) showing moderate diffuse optic disc pallor (solid arrows), moderate arteriolar attenuation (dashed arrows), dull macular and foveal reflexes (arrow heads), and normal retinal background.

Brain MRI at the age of **four years** showed bilateral confluent white matter changes—mainly in periventricular and splenium areas. MRS showed moderately decreased NAA and elevated Choline. VLCFA was mildly elevated with C26:0 at 1.24 $\mu\text{mol/L}$ (0.00 - 1.08) and C24:0/C22:0 ratio at 1.288 (0–1.158), with a normal pristanic acid level. WES (Breda Genetics, Brescia, Italy) identified a homozygous deletion in exon 4 of the *ACBD5* gene.

Case five (male, 30 y)

This patient was born to consanguineous parents. Photophobia and nystagmus were noted in the first months of his life with progressive visual impairment, due to which he attended a school for children with visual needs. Gait unsteadiness was noted first at the age of 15 years. At 17, he had progressive walking difficulties and ataxia. He did not report any swallowing difficulties and has no dysarthria. There was no history of urine or bowel incontinence, seizures, memory impairment or behavioral changes. Ophthalmology assessment at 21 showed nystagmus, severe visual impairment, disc pallor, attenuated vessels, and pigmentary changes at the macula. ERG confirmed severe cone-rod dysfunction. NCS at the age of 25 years showed mild motor neuropathies (axonopathy). Brain MRIs at 17 and 25 years of age are detailed in Table 1 and Figure 3. WES (Centogene, Rostock, Germany) identified a homozygous deletion in exon 4 of the *ACBD5* gene.

The patient is university-educated, and currently employed as a medical recorder in a hospital. Physical examination showed a thin man with body mass index of 19 and head circumference at second percentile. His sensations of temperature, pain, and touch were intact with an impaired sense of joint positions of the lower limbs, intention tremor, and dysmetria. He had normal muscle tone, hyperreflexia and bilateral extensor plantar response. Muscle strength was normal in the upper limbs. However, lower limbs had bilateral pes cavus and significant distal weakness with no joint contractures. The patient was fully wheelchair-dependent.

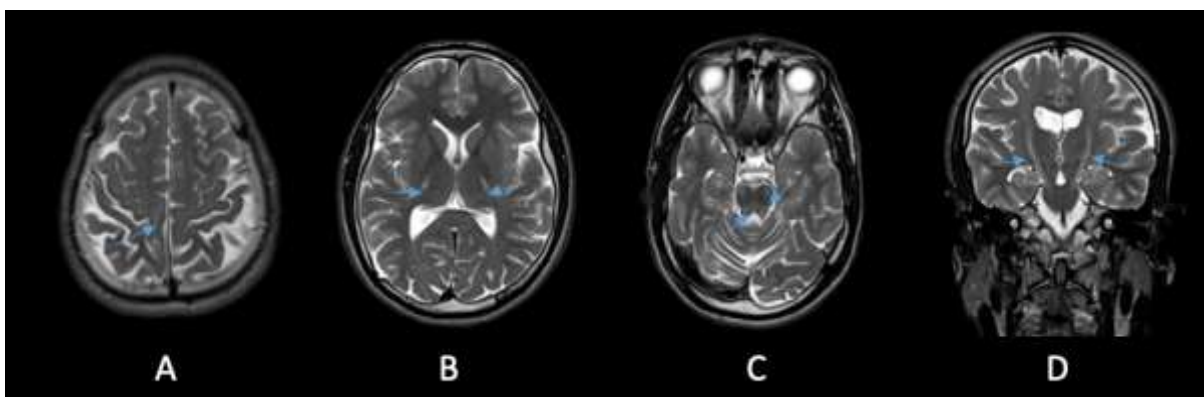


Figure 3: (Case 5) MRI of brain taken at 25 years of age. **A–C:** Axial T2-weighted images showing hyperintensity of corticospinal tracts (arrows) bilaterally from perirolandic cortex (A) throughout posterior limb of internal capsule (B) reaching the pontine level (C); visible atrophic changes of cerebellum (C) and parietal lobes on brain convexity (A); also presenting signal alteration at posterior pontine tegmentum and both superior cerebellar peduncles (C). **D:** coronal T2W image showing bilateral involvement of corticospinal tract.

Table 1: Summary of the clinical features of five Omani patients with ACBD5-related retinal dystrophy with leukodystrophy.

	Family 1		Family 2	Family 3	Family 4
	Case 1	Case 2	Case 3	Case 4	Case 5
Sex & age at presentation	Male; 10 y	Male; 4 y	Female; 7 y	Female; 10 y	Male; 30 y
Anthropometry:					
Head circumference	-3.6SD	10 th percentile	-3SD	All at the 5 th – 10 th percentile	2 nd percentile
Weight	-2.7SD	8 th percentile	-4.8SD		57 kg
Height	-2.7SD	2 nd percentile	-4.5SD		171 cm
Genetic variant in ACBD5 gene	Homozygous deletion of exons 7–8	Homozygous deletion of exons 7–8	Homozygous deletion of exons 7–8	Homozygous deletion of exon 4	Homozygous deletion of exon 4
Ophthalmological features					
Age at presentation	2 years	2.5 years	18 months	16 months	17 years
Age of onset	3 months	3 months	5–6 months	3 months	< 6 months
Age of last ophthalmic assessment	9 years	4 years	7 years	7 years	21 years
Photophobia	+	+	+	+	+
Nystagmus (horizontal, pendular)	+	+	+	+	+
Visual acuity at presentation (Qualitative assessment)	OU <6/60*	OD: FF; CUSM OS: FF; CUSM	OD: FF; CSM OS: FF; CSM	OU: <6/60*	OU: <6/60*
Vision when last seen	OU <6/60	OU FF; CUSM	OU < 6/60*	OU: < 6/60	OU: <6/60

Refractive error	Mild myopic astigmatism	Mild mixed astigmatism	Moderate myopic astigmatism	Mild compound astigmatism	Mild myopia
Pupils' reaction to light	Sluggish	Sluggish	Sluggish	Sluggish	Sluggish
Fundus					
Disc pallor	+	+	+++	++	++
Vessel attenuation	++	+	+++	++	+++
Macula	Atrophic	Dull	Atrophic	Dull	Dull
Pigmentary changes in the retinal background	Not present	Not present	Mild granularity	Not present	Mild granularity
Electroretinogram (ERG)	Severe cone-rod dysfunction	Severe cone-rod dysfunction	Severe cone-rod dysfunction	Severe cone - moderate rod dysfunction	Severe cone-rod dysfunction
Age when ERG done	2 years	2.5 years	2 years	7 years	25 years
Neurological features					
Age of onset of symptoms	14 months	3 years 6 months	11 months	13–14 months	15yrs
Central hypotonia	+	+	+	NA	NA
Lower limbs Spasticity	+	-	+	+	+
Intention tremor	+	+	-	+	+
Cognitive disabilities	Mild intellectual disability	Not assessed	Learning difficulty; no formal assessment	Learning difficulty; no formal assessment	No
Overall motor function	Wheelchair-bound	Can walk with support	Pull up to stand and cruise around furniture	Able to walk with support	Wheelchair-bound

Nerve conduction studies (NCS) (age when detected)	normal (6 years)	normal (3 years 7 months)	not done	not done	mild motor neuropathy (25 years)
Brain MRI findings	Bilateral signal abnormalities in deep white matter with posterior pattern	Bilateral deep white matter signal abnormalities with posterior pattern	Bilateral signal abnormalities of deep white matter with posterior pattern	Bilateral confluent white matter changes mainly periventricular and splenium	Abnormal signal in bilateral cs tracks reaching up to the brain stem, atrophy of brain stem, cerebellum, and thoracic spinal cord

* Vision tested with sugar pearl test (single dark pearl identification is equivalent to Snellen 6/60)

SD: standard deviation; CSM: Central, Steady, Maintained; CUSM: central, steady, unmaintained; FF: Fixing and Following; US: Unsteady; OD: right eye, OS: left eye, OU: both eyes; ACBD5: Acyl-coenzyme A-binding domain-containing protein 5. Grading of findings: + mild, ++ moderate, +++ severe, - absent; ERG: Electroretinogram; NCS: nerve conduction studies; CS: corticospinal, MRI: magnetic resonance imaging; NA: not available

Discussion

As explained earlier, the physiological importance of the *ACBD5* gene in peroxisomal β -oxidation of VLCFAs was first discovered in 2013.⁵ The cardinal features of *ACBD5*-related retinal dystrophy with leukodystrophy (RDLKD) were consistent with subsequent reports and included infantile-onset nystagmus followed by motor deterioration, spasticity, cerebellar symptoms, and cognitive disability.^{3,6,7} Ferdinandusse et al. showed that *ACBD5* defect leads to accumulation of VLCFAs due to their impaired peroxisomal β -oxidation. They demonstrated increased levels of C26:0 lysophosphatidylcholine (C26:0 lysoPC) and/or C26-acylcarnitine in plasma, dried blood spot, and fibroblasts from their patient with other peroxisomal parameters in blood (plasma phytanic acid, pristanic acid, pipercolic acid, and plasmalogens in erythrocytes) being normal, in a pattern that was similar to patients with X-linked adrenoleukodystrophy. The group also confirmed the absence of *ACBD5* protein in the HeLa cells (HeLa Δ *ACBD5*) by immunoblotting.³

The oldest patient reported to date, a 36-year-old Brazilian woman, who, in addition to being wheelchair-bound, had developed significant cognitive decline, upper extremity weakness, difficulty with fine motor movements, sphincter incompetence, and neurogenic bladder during her teens, and severe dysphagia with gastrostomy dependence in her thirties.⁶ However, the child from UAE had additional malformations exhibited by facial dysmorphism and cleft palate. This patient, interestingly, was homozygous for the exon 7 and 8 deletion in the *ACBD5* gene, which was also identified in three patients in our cohort. None of our five patients (including the three with the same variant as in the UAE patient), the Brazilian woman,⁶ or the Turkish sisters,⁷ had the extra features described by the Ferdinandusse group, supporting the assumption that the malformations observed in the UAE child were unlikely to be related to *ACBD5* deficiency.

The neurological symptoms of all the four children in the current series were evident by the age of three. Our adult patient (case 5), however, had no motor limitations until he was fifteen. He is also our only patient with normal cognitive function at the age of 30. It is difficult to correlate the differences in his neurological function on his genotype, as he shares the same homozygous deletion of exon 4 with our case 4 patient, whose neurological manifestations began when she was three months old.

Growth restriction and microcephaly were also frequent features among the patients in the current series, specifically those who had a homozygous deletion in exons 7 and 8, and there was no growth abnormality or microcephaly in cases 4 and 5, both harboring the same homozygous out-of-frame deletion of exon 4.

Retinopathy is a recurrent pathology in patients suffering from disorders in peroxisome biogenesis. Research on rodent retina⁸ was able to detect peroxisomes in all retinal layers, with high expression of *ACBD5* in retinal outer segments.⁹ The latter finding suggests that polyunsaturated fatty acids (PUFA) and VLCFA, besides being recycled to the photoreceptors, can be taken up and degraded by peroxisomes.⁹ It was also shown that *ACBD5* functions to tether peroxisomes to the endoplasmic reticulum.¹⁰ Retinopathy in *ACBD5* mutations is assumed to be related to impairment in these functions and impaired metabolism of VLCFA and PUFA that are crucial components of the retina. Retinal dystrophy occurred in virtually all patients with *ACBD5* null mutations reported to date and their ocular manifestations were very similar in the age of onset, presenting symptoms, fundus findings, and ERG finding of cone-rod dystrophy. It seems that retinal involvement does not correlate with age of onset or severity of the neurological disease, leading to the assumption that milder missense variants may manifest as isolated non-syndromic retinal dystrophy.

The VLCFAs level was assessed in three of our patients which showed a similar pattern to the four previously reported patients with elevations of C26:0 with or without elevations of C24:0, C26:0/C22:0 and C24:0/C22:0 ratios. Although nonspecific, this biochemical parameter can provide an important clue for diagnosing this form of peroxisomal disorder in patients who have consistent clinical findings.

The neuroradiological features of patients in this series are fairly consistent and show a recognizable pattern similar to previously reported patients with hypomyelination with diffuse hyperintense T2 and Flair signal abnormality in white matter with relative sparing of the subcortical U fibers that extend along the cerebrospinal tracks involving bilateral cerebral peduncles up to the brain stem. The demonstration of atrophic changes in the bilateral cerebellar hemispheres, brainstem, and the thoracic spinal cord in the oldest patient in this series is similar to the oldest reported patient⁶ and supports the progressive neurodegenerative nature postulated for this disease. The metabolites revealed by MRS were also consistent in all our five patients and in previously reported patients with decreased NAA and increased choline.

Conclusion

This report supports the previous observations that ACBD5-related RDLKD is a well-recognized neurodegenerative disease of peroxisomal fatty acids beta-oxidation with early onset cone-rod dystrophy and variable age of onset of neurological decline that is characterized by progressive spastic paraparesis, ataxia and cognitive decline. RDLKD should be included in the differential diagnosis of patients with retinal dystrophy associated with progressive spastic paraparesis and cerebellar symptoms.

Disclosure

The authors declare no conflicts of interest. Informed consent was obtained from the adult patient and from the legal guardians of all pediatric patients.

Acknowledgments

We wish to acknowledge all patients and their families for their participation by offering relevant data and giving consent. We also thank Ms Asila Al Habsi, the Biochemical Genetics Specialist Nurse for following up the patients and obtaining consents, and Dr Muna Al Ruhaili, Ophthalmology resident, for her help in extracting patient information.

References

1. Waterham HR, Ferdinandusse S, Wanders RJ. Human disorders of peroxisome metabolism and biogenesis. *Biochim Biophys Acta* 2016 May;1863(5):922-933.
2. Wiese S, Gronemeyer T, Ofman R, Kunze M, Grou CP, Almeida JA, et al. Proteomics characterization of mouse kidney peroxisomes by tandem mass spectrometry and protein correlation profiling. *Mol Cell Proteomics* 2007 Dec;6(12):2045-2057.
3. Ferdinandusse S, Falkenberg KD, Koster J, Mooyer PA, Jones R, van Roermund CW, et al. ACBD5 deficiency causes a defect in peroxisomal very long-chain fatty acid metabolism. *J Med Genet* 2017 May;54(5):330-337.
4. Yagita Y, Shinohara K, Abe Y, Nakagawa K, Al-Owain M, Alkuraya FS, et al. Deficiency of a retinal dystrophy protein, Acyl-CoA binding domain-containing 5 (ACBD5), impairs peroxisomal β -oxidation of very-long-chain fatty acids. *J Biol Chem* 2017 Jan;292(2):691-705.
5. Abu-Safieh L, Alrashed M, Anazi S, Alkuraya H, Khan AO, Al-Owain M, et al. Autozygome-guided exome sequencing in retinal dystrophy patients reveals pathogenetic mutations and novel candidate disease genes. *Genome Res* 2013 Feb;23(2):236-247.
6. Bartlett M, Nasiri N, Pressman R, Bademci G, Forghani I. First reported adult patient with retinal dystrophy and leukodystrophy caused by a novel ACBD5 variant: A case report and review of literature. *Am J Med Genet A* 2021 Apr;185(4):1236-1241.
7. Gorukmez O, Havalı C, Gorukmez O, Dorum S. Newly defined peroxisomal disease with novel ACBD5 mutation. *J Pediatr Endocrinol Metab* 2021 Oct;35(1):11-18.
8. Das Y, Roose N, De Groef L, Fransen M, Moons L, Van Veldhoven PP, et al. Differential distribution of peroxisomal proteins points to specific roles of peroxisomes in the murine retina. *Mol Cell Biochem* 2019 Jun;456(1-2):53-62.
9. Bazan NG. Cellular and molecular events mediated by docosahexaenoic acid-derived neuroprotectin D1 signaling in photoreceptor cell survival and brain protection. *Prostaglandins Leukot Essent Fatty Acids* 2009;81(2-3):205-211.

Oman Medical Journal (2025) Vol. 39, No. 6: -

DOI 10.5001/omj.2025.34

10. Hua R, Cheng D, Coyaud É, Freeman S, Di Pietro E, Wang Y, et al. VAPs and ACBD5 tether peroxisomes to the ER for peroxisome maintenance and lipid homeostasis. *J Cell Biol* 2017 Feb;216(2):367-377.