

An Abnormal Fixation of Falciform Ligament Discovered Incidentally During Laparoscopic Cholecystectomy: A Factor of Difficult Laparoscopy

Dharmendra K. Pipal^{1*}, Prakash Viswa^S and Vibha Rani²

Department of General Surgery, All India Institute of Medical Sciences, Gorakhpur, India

Department of Gynaecology and Obstetrics, All India Institute of Medical Sciences, Gorakhpur, India

Received: 29 May 2023

Accepted: 8 October 2023

*Corresponding author: dr.dharmendrapipal2007@gmail.com

DOI 10.05001/omj.2025.32

Abstract

Surgeons need to be aware of the clinical significance of congenital abnormalities and anomalies in the human body. The largest organ in the digestive system is the liver, which is supported by various peritoneal folds called ligaments. One of them is the falciform ligament, which holds the liver to the anterior abdominal wall and carries an obliterated umbilical vein. The abnormal falciform may cause acute surgical emergencies like intestinal obstruction or volvulus that increase morbidity and mortality. We report a case report of a 24-year-old male patient who underwent laparoscopic cholecystectomy for symptomatic gallbladder stones. We encountered an aberrant falciform ligament attachment during the laparoscopy, which complicated the creation of the pneumoperitoneum. The aim of this case report is to make surgeons aware of abnormal attachment of the falciform ligament in the region of Veress needle insertion that can raise problems during the initial step of laparoscopy, i.e., pneumoperitoneum creation by blind technique with the help of either the Veress or direct trocar insertion.

Keywords: Nonfixation, Falciform ligament, bowel obstruction, Laparoscopic cholecystectomy

Introduction

There are many structural variations in the organs of the abdominal cavity; however, those connected to the ligamental attachment of the liver are crucial from a therapeutic standpoint. One of these is the falciform ligament, which connects the liver to the umbilical ring by extending from the anterior abdominal wall to the diaphragm.¹ Previous research has indicated that there are structural differences between adults and children in the falciform ligament's thickness, stretch, and development.² Adult falciform ligaments have a mean length and thickness of about 9.9 cm and 6 mm, respectively, according to earlier studies. Additionally, the obliterated umbilical vein is enclosed by this ligament.³ Falciform ligament fixation may not occur if the peritoneum fails to merge with the umbilical vein. In the pediatric age group, this anomaly has been linked to newborn intestinal obstruction and internal herniation.

Case Report

We are reporting a case of a 24-year-old male patient who presented with intermittent upper abdominal pain with dyspepsia for the last six months. On ultrasound, he had gallbladder stones with a normal dimension, including the diameter of the CBD (common bile duct). The hepatic functions in laboratory tests were within the normal range. He was planned for the laparoscopic cholecystectomy. During surgery, the pneumoperitoneum was not able to be created via the Veress needle, and the pressure was high during insufflation. Therefore, Hassan's technique was opted for. After the introduction of the telescope, a diagnostic laparoscopy was performed, and everything was normal except the insufficiently formed falciform ligament, which was not dividing the liver into two halves as it normally does. The liver was unsupported on the undersurface of the anterior abdominal wall, and a thick bulky fat-laden band of the umbilical vein extended from the umbilicus to the liver, making a congenital

band and mainly located at the umbilical region; [Figures 1]. The liver was extending from the right side of the abdomen to the left without any separation by the falciform ligament [Figure 1].

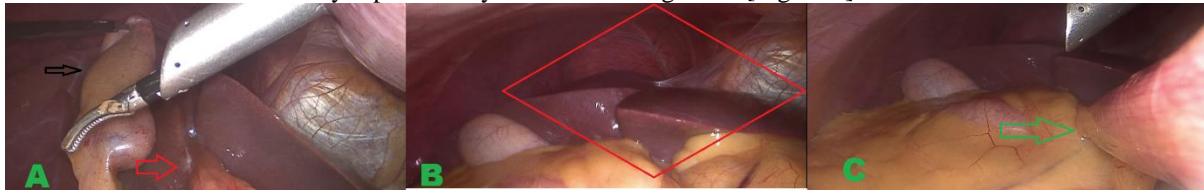


Figure 1: (a) Umbilical vein band extending up to the undersurface of the liver (Marked by red arrow) and retracted gall bladder (marked by black arrow). (b) Showing completely unsupported liver to the anterior abdominal wall due to the absence of attachment of falciform ligament to the anterior abdominal wall (Depicted by a red rectangular area). (c) A thick fat-laden band of umbilical vessels extending from the umbilicus to the liver without extended falciform to the abdominal wall (Marked by a green arrow)

Discussion

The double-layered falciform ligament physically divides the liver into right and left segments. This ligament connects the lower edge of the diaphragm to the liver's front-to-back surface. The falciform ligament runs along the front of the abdominal wall from the parietal peritoneum to the visceral peritoneum along the liver surface. It divides the upper part of the supra-mesocolic gaps into two subphrenic spaces.⁴ Torsion or twisting of the fatty appendageal pockets of the said ligament is extremely rare and known as intra-abdominal focal fat infarction (IFFI), which clinically resembles other acute surgical conditions.⁵ The ligament is a crucial reference point for abdominal and gallbladder surgeries. It hides the hepatic vein, which drains the liver into the IVC (inferior vena cava).

Usually, the ligament is mainly attached to the anterior abdominal wall, well away from the umbilicus, but in this case, it was not so; rather, the thick and bulky end of the ligament was in the umbilicus region, which was posing difficulty while creating the pneumoperitoneum. During the difficulty in the creation of pneumoperitoneum, the palmar point approach or open Hassan's technique was the alternative, safer way of creating pneumoperitoneum, which is well described in the literature, and we opted for the second one.

The round ligament, which enters the umbilicus at the free end of the falciform ligament, also acts as an important landmark for the inner anterior abdominal wall.⁶ The umbilical vein endures as a solid, band-like structure. Small bowel herniation is the most frequent internal hernia and has been linked to this anomaly in 0.2% of cases.⁷ In a baby with pyloric stenosis, an anomalous umbilical vein caused intestinal obstruction in 1960, according to a case study by Hoffbert and Strachman.⁸

Few articles recommend removing the umbilical vein if it is found by accident because of the risk of intestinal obstruction or volvulus in the future. We did not do this because the umbilical vein helps support the liver, the patient had no episodes of intestinal obstruction, and the patient's preoperative symptoms and ultrasonography of the abdomen pointed to gall bladder stones only.

Conclusion

To conclude, it is advisable that if there is any difficulty during the creation of pneumoperitoneum for laparoscopy, surgeons should keep this abnormal falciform ligament attachment and opt for another way of creating pneumoperitoneum, i.e., Hassan's technique or palmar's point entry.

Disclosure

The authors declared no conflicts of interest. Consent was obtained from the patient.

References

1. Ozkececi ZT, Ozsoy M, Celep B, Bal A, Polat C. A rare cause of acute abdomen: an isolated falciform ligament necrosis. *Case Rep Emerg Med* 2014;2014:570751. . Published online 17 Jun 2014.

2. Han SY. Variation in falciform ligament with pneumoperitoneum. *J Can Assoc Radiol* 1980 Sep;31(3):171-173.
3. Lakdawala M, Chaube SR, Kazi Y, Bhasker A, Kanchwala A. Internal hernia through an iatrogenic defect in the falciform ligament: a case report. *Hernia* 2009 Apr;13(2):217-219. . Published online 13 Sep 2008.
4. Indiran V, Dixit R, Maduraimuthu P. Unusual Cause of Epigastric Pain: Intra-Abdominal Focal Fat Infarction Involving Appendage of Falciform Ligament - Case Report and Review of Literature. *GE Port J Gastroenterol* 2018 Jun;25(4):179-183. . Published online 15 Nov 2017.
5. Justaniah AI, Scholz FJ, Katz DS, Scheirey CD. Perigastric appendagitis: CT and clinical features in eight patients. *Clin Radiol* 2014 Dec;69(12):e531-e537. . Erratum in: *Clin Radiol*. 2015 Apr;70. 4.: 457. PMID: 25278036.
6. Garbar V, Newton BW. Anatomy, Abdomen and Pelvis: Falciform Ligament. [Updated 2022 Jul 25]. In: StatPearls [Internet]. Treasure Island (FL): StatPearls Publishing; 2023 Jan-.
7. Wiseman S. Internal herniation through a defect in the falciform ligament: a case report and review of the world literature. *Hernia* 2000;4:117-120. .
8. Hoffert PW, Strachman J. Intestinal obstruction due to aberrant umbilical vein and hypertrophic pyloric stenosis. Case in a two-week-old infant. *Arch Surg* 1960 Dec;81:890-892. .