

Ocular Sebaceous Carcinoma: The Great Masquerader

Abdullah Al-Mujaini,¹ Buthaina Sabt,¹ Aisha Al-Hamdani,²

From the ¹Department of Ophthalmology, Sultan Qaboos University Hospital, Muscat, Sultanate of Oman

²Department of Pathology, Sultan Qaboos University Hospital, Muscat, Sultanate of Oman

Received: 25 May 2009

Accepted: 13 June 2009

Address correspondence and reprint requests to: Dr. Abdullah A-Mujaini, Department of Ophthalmology, Sultan Qaboos University Hospital, Muscat, Sultanate of Oman

E-mail: mujainisqu@hotmail.com

Al-Mujaini A et al, OMJ. 24, 226-227 (2009); doi:10.5001/omj.2009.46

Ocular sebaceous carcinoma is a rare condition and accounts for 1% to 5.5% of eyelid malignancies and is the third most common eyelid malignancy after basal cell and squamous cell carcinoma. It usually affects elderly women, has a high rate of local recurrence, and a tendency to regional and distant metastases.

The authors hereby describe a 51-year-old female who was presented with the typical symptoms and signs of peri-ocular malignancy. Histopathologic evaluation from the excised involved area confirmed the diagnosis of ocular sebaceous carcinoma.

Case report

A 51-year-old female patient was presented with a history of slow growing mass involving the right upper eyelid. Past ocular history was significant for incomplete removal of the same mass at a private clinic, three months prior to this presentation.

Discussion

Ophthalmic examination revealed visual acuity of 20/20 bilaterally. External examination of the right upper lid showed a discrete, large nodule with central vascularization and hemorrhagic ulceration. (Fig. 1) No lymph nodes were palpated. The rest of ophthalmic examination was unremarkable.

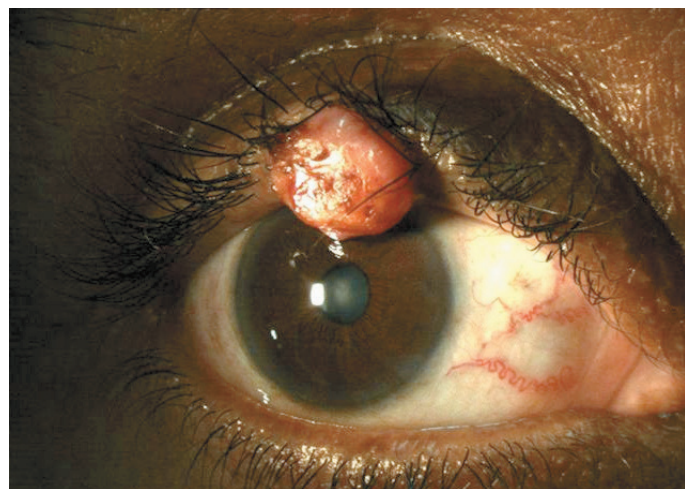


Figure 1: Large Nodule with Central Vascularization and Hemorrhagic Ulceration

A provisional clinical diagnosis of peri-ocular malignancy was made and the patient was advised excisional biopsy. A wide surgical resection with 2-4 mm of clinically uninvolved skin from the temporal margin, nasal margin and bed of the tumor was performed to ensure complete removal of the lesion. The eyelid was reconstructed by re-approximating the surgical margins. (Fig. 2)

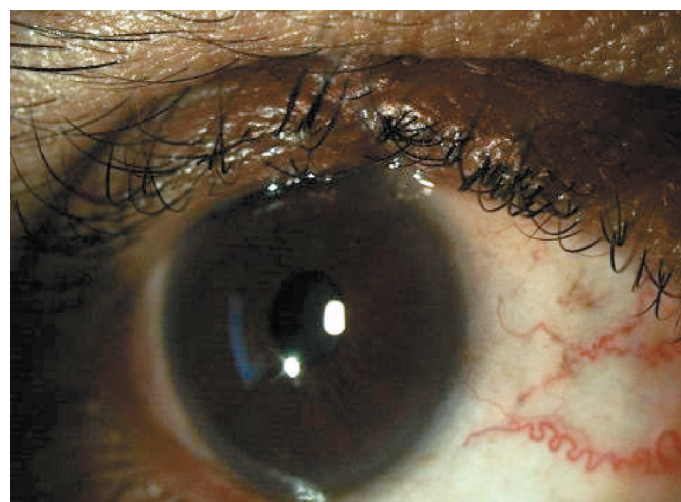

Figure 2: Reconstructed Eyelid

Hematoxylin and Eosin stained sections from the specimen showed a poorly differentiated malignant tumor consisting of irregular nodules and islands of atypical cells with enlarged vesicular nuclei, prominent nucleoli and eosinophilic to finely vacuolated cytoplasm. Mitoses and areas of necrosis were noted. Basaloid cells and focal keratinization were observed. Foci of the carcinoma - in - situ changes were also observed in the overlying epidermis and the adjacent tissue. Tumor cells were positive for epithelial membrane antigen (EMA) and negative for carcinoembryonic antigen (CEA). The morphology and the immunohistochemical profiles were consistent with invasive poorly differentiated sebaceous carcinoma with incompletely excised temporal margin. (Fig. 3)

Another surgical resection to clear the temporal margin was planned, but the patient refused the treatment. Ocular sebaceous carcinoma is a threatening malignancy affecting the elderly people with a high rate of local recurrence and a tendency to regional as

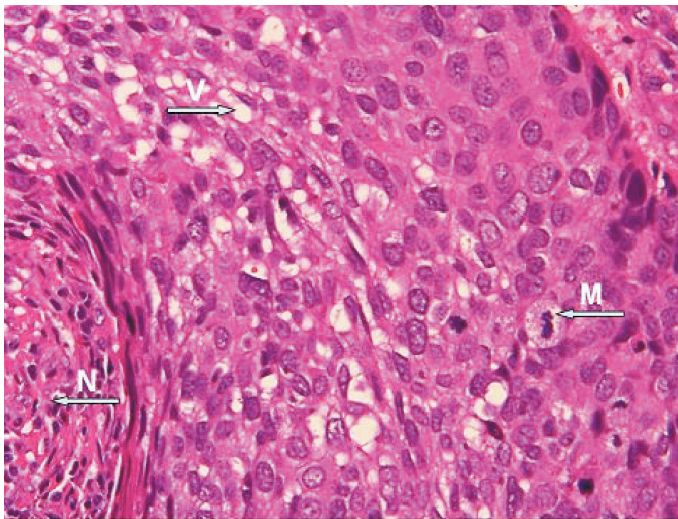


Figure 3: Hematological Section of the Malignant Tumor

well as distant metastases.¹ It has a wide range of clinical presentations. It may present as inflammatory conditions such as; blepharo-conjunctivitis, chalazion or superior limbic keratoconjunctivitis or may masquerade as other ocular tumors such as; basal cell carcinoma or squamous cell carcinoma.²

Sebaceous carcinoma has a tendency to invade the peri-ocular region where the upper eyelid is most commonly involved followed by the lower eyelid and the caruncle.²

Histopathologically, two important features differentiate sebaceous carcinoma from other periocular malignancies. First, unlike single origin of others, sebaceous carcinoma appears to arise from multifocal origins and secondly, it tends to spread superficially in a pattern known as pagetoid spread, unlike radial spread of other common peri-ocular tumors namely basal cell and squamous cell carcinomas.³

A delay in clinical diagnosis which can be attributed primarily to the ability of this tumor to masquerade as more benign conditions often leads to inappropriate management and increased morbidity and mortality rates.¹ The actual reported sebaceous carcinoma-related mortality is around 6%.²

Surgical excision is the main choice of treatment. Current studies demonstrate that Mohs micrographic surgery provides maximal tissue conservation and lower recurrence rates.^{1,3} Other therapeutic modalities which might be considered to improve the visual as well as systemic prognosis include cryotherapy, chemotherapy and radiotherapy.⁴

Acknowledgements

The authors reported no conflict of interest and no funding has been received on this work.

References

1. Buitrago W, Joseph AK. Sebaceous carcinoma: the great masquerader: emerging concepts in diagnosis and treatment. *Dermatol Ther* 2008 Nov-Dec;21(6):459-466.
2. Shields JA, Demirci H, Marr BP, Eagle RC Jr, Shields CL. Sebaceous carcinoma of the eyelids: personal experience with 60 cases. *Ophthalmology* 2004 Dec;111(12):2151-2157.
3. Snow SN, Larson PO, Lucarelli MJ, Lemke BN, Madjar DD. Sebaceous carcinoma of the eyelids treated by mohs micrographic surgery: report of nine cases with review of the literature. *Dermatol Surg* 2002 Jul;28(7):623-631.
4. Shields JA, Demirci H, Marr BP, Eagle RC Jr, Shields CL. Sebaceous carcinoma of the ocular region: a review. *Surv Ophthalmol* 2005 Mar-Apr;50(2):103-122.